



American Path Labs

Timing : Mon. to Sat. 8 am to 9:30 pm

Sunday 8 am to 4 pm

| | | | | | |
|---------|------------|---------|---------|-----|---|
| Date | 05/09/2019 | Srl No. | 1 | Sex | F |
| Name | MRS. MEENA | Age | 43 Yrs. | | |
| Ref. By | SELF | | | | |

| Test Name | Value | Unit | Normal Value |
|-----------|-------|------|--------------|
|-----------|-------|------|--------------|

HAEMATOLOGY TEST REPORT

COMPLETE BLOOD COUNT

| | | | |
|------------------------------|-------|-------------------|--------------|
| HAEMOGLOBIN (Hb) | 11.8 | GM % | 11.0 - 15.0 |
| TLC (Total Leucocyte Count) | 7,700 | /cu mm | 4000 - 11000 |
| DIFFERENTIAL LEUCOCYTE COUNT | | | |
| NEUTROPHILS | 55 | % | 40 - 80 |
| LYMPHOCYTES | 35 | % | 20 - 45 |
| MONOCYTES | 05 | % | 1 - 8 |
| EOSINOPHILS | 05 | % | 1 - 6 |
| BASOPHILS | 00 | % | 0 - 1 |
| R B C (Red Blood Cell Count) | 4.3 | Millions/cm m | 3.5 - 5.0 |
| PCV / Hct (Hematocrit) | 35.4 | % | 34 - 47 |
| M C V (Mean Corp Volume) | 82.3 | fl | 76.0 - 96.0 |
| M C H (Mean Corp Hb) | 27.4 | pg | 27.0 - 32.0 |
| M C H C (Mean Corp Hb Conc) | 33.3 | g/dl | 30.0 - 35.0 |
| PLATELET COUNT | 130 | x 10 ³ | 150 - 450 |
| MALARIA (CARD) ANTIGEN | | | |
| Malaria (P vivax) | | NEGATIVE | |

Lab Technician

Dr. Sakesh K. Agrawa

M.B.B.S, D.C.P. (Path)

U.P.M.C.Regd. No. : 7402/16.5.16

All tests have technical limitation, corroborative clinicopathological interpretation is mandatory. In case of disparity, test may be repeated immediately.

• Bihari Lal Plaza, Ground Floor, Opp. New Bus Stand, Mathura-281001 | Mob.: 7454842627, 7454852627 | Email : japl2016@yahoo.com

NOT VALID FOR MEDICO LEGAL PURPOSE

Fully Computerized Lab.



JAI SHREE



American Path Labs

Timing : Mon. to Sat. 8 am to 9:30 pm
Sunday 8 am to 4 pm

| | | | | | |
|---------|------------|---------|---------|-----|---|
| Date | 05/09/2019 | Srl No. | 1 | Sex | F |
| Name | MRS. MEENA | Age | 43 Yrs. | | |
| Ref. By | SELF | | | | |

| Test Name | Value | Unit | Normal Value |
|--------------------------|----------|------|--------------|
| Malaria (P. falciparum). | NEGATIVE | | |

SEROLOGY TEST REPORT

WIDAL TEST

| | 1/20 | 1/40 | 1/80 | 1/160 | 1/320 |
|------------|------|------|------|-------|-------|
| TYPHI "O" | + | + | + | - | - |
| TYPHI "H" | + | + | + | - | - |
| TYPHI "AH" | + | + | - | - | - |
| TYPHI "BH" | + | + | - | - | - |

THE RESULTS OF A SINGLE TEST SHOULD BE INTERPRETED WITH CAUTION IT IS DIFFICULT TO LAY DOWN THE LEVELS OF SIGNIFICANCE THROUGH IT IS GENERALLY STATED THAT TITRES OF 1/100 OR MORE FOR O AGGLUTININS AND 1/200 OR MORE FOR H AGGLUTININS ARE SIGNIFICANT.

BIOCHEMISTRY TEST REPORT

| | | | |
|-----------------------------|------|------|--------------|
| BLOOD SUGAR FASTING | 95.2 | mg % | 60.0 - 110.0 |
| KIDNEY FUNCTION TEST | | | |
| BLOOD UREA | 27.3 | mg % | 16.0 - 48.0 |

Lab Technician

Dr. Sakesh K. Agrawal

M.B.B.S, D.C.P. (Path)
U.P.M.C.Regd. No. : 7402/16.5.1

All tests have technical limitation, corroborative clinicopathological interpretation is mandatory. In case of disparity, test may be repeated immediately.

• Bihari Lal Plaza, Ground Floor, Opp. New Bus Stand, Mathura-281001 | Mob.: 7454842627, 7454852627 | Email : japl2016@yahoo.com
NOT VALID FOR MEDICO LEGAL PURPOSE Fully Computerized Lab



American Path Labs

Timing : Mon. to Sat. 8 am to 9:30 pm

Sunday 8 am to 4 pm

| | | | | | |
|---------|------------|--------|---------|-----|---|
| Date | 05/09/2019 | Srl No | 1 | Sex | F |
| Name | MRS. MEENA | Age | 43 Yrs. | | |
| Ref. By | SELF | | | | |

| Test Name | Value | Unit | Normal Value |
|------------------|--------------|---------|---------------|
| SERUM CREATININE | 1.0 | mg % | 0.6 - 1.1 |
| SERUM URIC ACID | 5.0 | mg % | 2.0 - 6.5 |
| Serum Sodium | 133.2 | mmol /L | 135.0 - 150.0 |
| S. Potassium | 4.8 | mmol /L | 3.5 - 5.0 |
| IONISED CALCIUM | 4.6 | mg/dL | 4.4 - 5.4 |

BIOCHEMISTRY TEST REPORT

LIPID PROFILE

| | | | |
|--|--------------|------|-----------|
| SERUM CHOLESTEROL <small>Optimal < 200 mg/dl Border Line High Risk 200 - 239 mg/dl High Risk > 240 mg/dl</small> | 222.8 | mg % | 120 - 200 |
| SERUM TRIGLYCERIDES <small>Optimal < 150 mg/dl Border Line High Risk 150 - 199 mg/dl High Risk 200 - 499 mg/dl Very High Risk > 500 mg/dl</small> | 121.8 | mg % | 60 - 150 |
| HDL CHOLESTEROL <small>Low < 40 mg/dl High > 60 mg/dl</small> | 41.3 | mg % | 35 - 60 |
| LDL CHOLESTEROL <small>Optimal < 100 mg/dl</small> | 157.2 | mg % | 50 - 100 |

Lab Technician

Dr. Sakesh K. Agrawal

M.B.B.S, D.C.P. (Pat)
U.P.M.C.Regd. No. : 7402/16.5.

All tests have technical limitation, corroborative clinicopathological interpretation is mandatory. In case of disparity, test may be repeated immediately.

• Bihari Lal Plaza, Ground Floor, Opp. New Bus Stand, Mathura-281001 | Mob.: 7454842627, 7454852627 | Email : japl2016@yahoo.co.in
NOT VALID FOR MEDICO LEGAL PURPOSE Fully Computerized Lab



JAI SHREE



American Path Labs

Timing : Mon. to Sat. 8 am to 9:30 pm
Sunday 8 am to 4 pm

| | | | | | |
|---------|------------|---------|---------|-----|---|
| Date | 05/09/2019 | Srl No. | 1 | Sex | F |
| Name | MRS. MEENA | Age | 43 Yrs. | | |
| Ref. By | SELF | | | | |

| Test Name | Value | Unit | Normal Value |
|--|-------|------|--------------|
| Near Optimal 100-129 Border Line High Risk 130 - 159 mg/dl High Risk - 160 -189 mg/dl very high > 190 mg/dl done by Alere Afinion. | | | |

| | | | |
|---|------|-------|--------|
| V L D L CHOLESTEROL | 24.3 | mg/dL | 2 - 30 |
| Male : 10 - 40 mg/dl Female : 10 - 40 mg/dl Child : 10 - 40 mg/dl | | | |

LIVER FUNCTION TEST

| | | | |
|---------------------------|-------|------|-------------|
| SERUM BILIRUBIN (TOTAL) | 0.68 | mg % | 0.1 - 1.0 |
| CONJUGATED (Direct) | 0.06 | mg % | 0.0 - 0.25 |
| UNCONJUGATED (Indirect) | 0.62 | mg % | 0.0 - 0.75 |
| SGOT /AST | 27.6 | U/L | 10.0 - 50.0 |
| SGPT /ALT | 29.2 | U/L | 10.0 - 50.0 |
| S. ALKALINE PHOSPHATASE | 188.7 | U/L | 10 - 270 |
| TOTAL PROTEIN | 6.8 | gm % | 6.0 - 8.0 |
| ALBUMIN | 3.4 | gm % | 3.5 - 5.5 |
| GLOBULIN | 3.4 | gm % | 1.8 - 3.6 |
| A/G RATIO | 1.0 | % | 1.0 - 2.3 |

Lab Technician

Dr. Sakesh K. Agrawal

M.B.B.S, D.C.P. (Pathology)
U.P.M.C.Regd. No. : 7402/16.5.1

All tests have technical limitation, corroborative clinicopathological interpretation is mandatory. In case of disparity, test may be repeated immediately.

• Bihari Lal Plaza, Ground Floor, Opp. New Bus Stand, Mathura-281001 | Mob.: 7454842627, 7454852627 | Email : japl2016@yahoo.com
NOT VALID FOR MEDICO LEGAL PURPOSE

Fully Computerized Lab



JAI SHREE



American Path Labs

Timing : Mon. to Sat. 8 am to 9:30 pm
Sunday 8 am to 4 pm

| | | | | | |
|---------|------------|---------|---------|-----|---|
| Date | 05/09/2019 | Srl No. | 1 | Sex | F |
| Name | MRS. MEENA | Age | 43 Yrs. | | |
| Ref. By | SELF | | | | |

| Test Name | Value | Unit | Normal Value |
|-----------|-------|------|--------------|
|-----------|-------|------|--------------|

HAEMATOLOGY TEST REPORT

| | |
|---------------------|----------|
| BLOOD GROUP (ABO) | 'A' |
| RH TYPING | POSITIVE |

***** End Of Report *****

Lab Technician

Dr. POOJA AGRAWAL
M.B.B.S., M.D.
(Pathologist)
Jai Shree American Path Lab
Mathura

Dr. Sakesh K. Agrawal

M.B.B.S., D.C.P. (Path)
U.P.M.C.Regd. No. : 7402/16.5.16

All tests have technical limitation, corroborative clinicopathological interpretation is mandatory. In case of disparity, test may be repeated immediately.

• Bihari Lal Plaza, Ground Floor, Opp. New Bus Stand, Mathura-281001 | Mob.: 7454842627, 7454852627 | Email : japl2016@yahoo.com

NOT VALID FOR MEDICO LEGAL PURPOSE

Fully Computerized Lab.



Mathura C.T. Scan Centre

Equipped With Mathura's First Multi Slice Spiral CT Scan Digital X-ray, O.P.G., Mammography
101-C, Krishna Nagar, Goverdhan Road, Mathura (U.P.) Ph. 0565-2425480, 9267407990, 8938881688

Dr. Sudhir Kumar Singh

M.B.B.S., D.C.H., D.M.R.D.

Managing Director & Consultant Radiologist
Registration No. 38385

REG...NO:

NAME: MRS. MEENA

REF...BY: DR.VIKAS MISHRA MS.

Ex-Resident - J.N. Medical College, A.M.U., Aligarh

Ex-Consultant Radiologist - { Janta X-ray & Ultrasonics, Moradabad
Advanced Diagnostics, Amritsar
Kriti Scanning Centre, Allahabad

DATE: 04/09/19

AGE/SEX: 40Y/F

2D REAL TIME SONOLOGICAL STUDY OF WHOLE ABDOMEN

LIVER: Is normal in size & parenchymal echotexture. Margins are regular. Intra hepatic bile ducts (IHD) are not dilated. No focal mass seen. Portal Vein is normal in caliber.

GALL BLADDER: Is well distended and shows normal wall thickness. No calculus/mass lesion is seen in its lumen. No pericholecystic collection is seen. C.B.D. is normal in caliber.

SPLEEN: is normal in size and shape. Echotexture appears normal.

PANCREAS: Shows normal size and echotexture. No focal mass / peripancreatic collection is seen.

RIGHT KIDNEY: Shows normal position, size, shape and contour. Cortical echotexture is normal. CMD is maintained. No calculus/hydronephrosis is seen.

LEFT KIDNEY: Shows normal position, size, shape and contour. Cortical echotexture is normal. CMD is maintained. *Left kidney shows apx-5.1mm calculus in middle calyx. No hydronephrosis is seen.*

No free fluid/ retroperitoneal adenopathy is seen.

U.BLADDER: is normal in distension and in wall thickness. Lumen is clear. No calculus or mass lesion is seen.

UTERUS: *is anteverted bulky in size (95.1x43.0x59.5mm) & shows apx-18.0x14.5x18.5mm hypoechoic mass lesion in posterior wall at body.* Endometrial thickness is 9.0mm. Cervix appears normal.

Both ovaries are normal in size and echotexture.

Cul de sac contains fluid.

**SUMMARY: LEFT RENAL CALCULUS WITH NO HYDRONEPHROSIS.
BULKY UTERUS WITH A FIBROID.
PID.**

DR. SUDHIR SINGH
CONSULTANT RADIOLOGIST

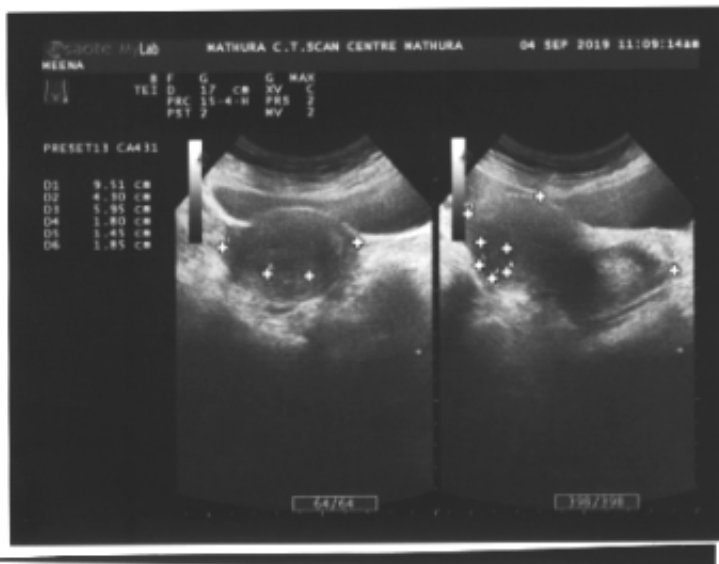
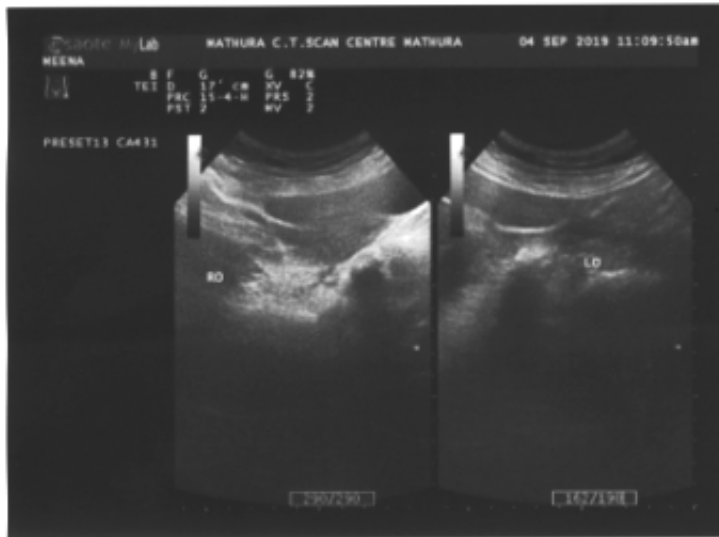
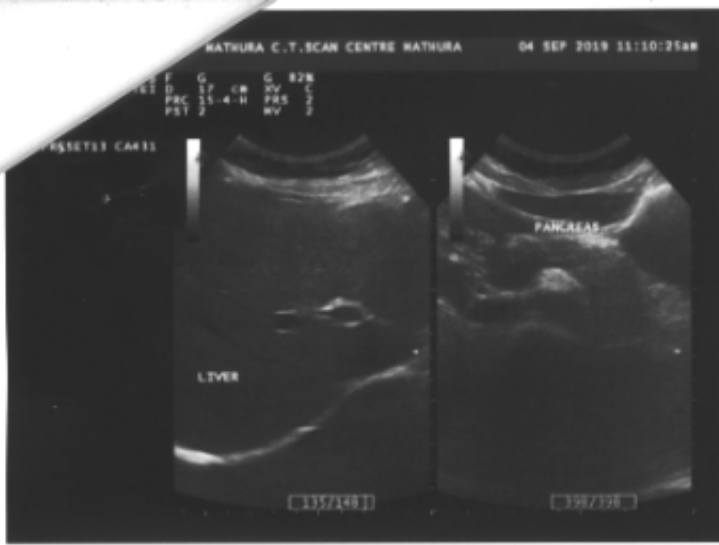
This is the professional opinion and not the diagnosis, based on imaging. It should be co-related clinically to arrive at conclusion. Best efforts were made during investigation, however in case of any Confusion/ Confirmation review can be done, free of cost. Not valid for medico-legal purpose.

THE NAME YOU TRUST.

नोट : रात्रि 11 बजे से प्रातः 5 बजे तक कार्य नहीं होता है।

Facilities :- Pulmonary Function Test (P.F.T.) Facility is also available

■ Whole Body CT Scan ■ Echocardiography ■ Ultrasound ■ T.M.T. ■ Mammography ■ Color Doppler ■ Digital X-ray ■ Digital O.P.G. ■ E.E.G. ■ E.C.G. ■ Pathology



T: 11

Working Hours - 9 A.M. - 8 P.M.
EMERGENCY - 8 P.M. to 11.00 Night
and 5 A.M. to 9 A.M.

Scan Centre

Spiral CT Scan Digital X-ray, O.P.G., Mammography
Ira (U.P.) Ph. 0565-2425480, 9267407990, 8938881688

Ex-Resident - J.N. Medical College, A.M.U., Aligarh
Ex-Consultant Radiologist - { Janta X-ray & Ultrasonics, Moradabad
Advanced Diagnostics, Amritsar
Kriti Scanning Centre, Allahabad

DATE: 04/09/19
AGE/SEX: 40Y/F

UDY OF WHOLE ABDOMEN

hotexture. Margins are regular. Intra
ocal mass seen. Portal Vein is normal

shows normal wall thickness. No
pericholecystic collection is seen. C.B.D.

xture appears normal.

exture. No focal mass / peripancreatic

1, size, shape and contour. Cortical
o calculus/hydronephrosis is seen.

shape and contour. Cortical echotexture
shows apx-5.1mm calculus in middle

seen.

in wall thickness. Lumen is clear. No

(95.1x43.0x59.5mm) & shows apx-
esion in posterior wall at body.

ears normal.

ture.

H NO HYDRONEPHROSIS.
OID.

DR. SUDHIR SINGH
CONSULTANTRADIOLOGIST

This is the professional opinion and not the diagnosis, based on imaging. It should be co-related clinically to arrive at conclusion. Best efforts were made during investigation, however in case of any Confusion/ Confirmation review can be done, free of cost. Not valid for medico-legal purpose.

THE NAME YOU TRUST.

नोट : रात्रि 11 बजे से प्रातः 5 बजे तक कार्य नहीं होता है।

Facilities :- Pulmonary Function Test (P.F.T.) Facility is also available

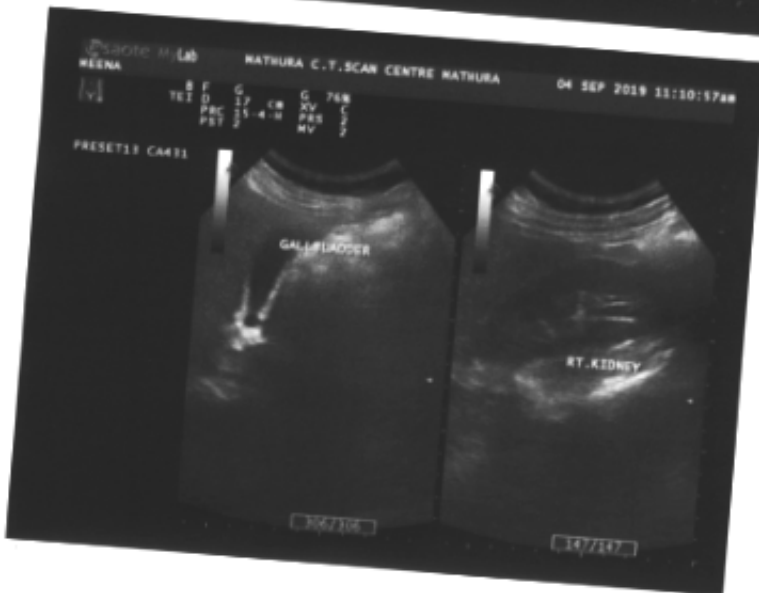
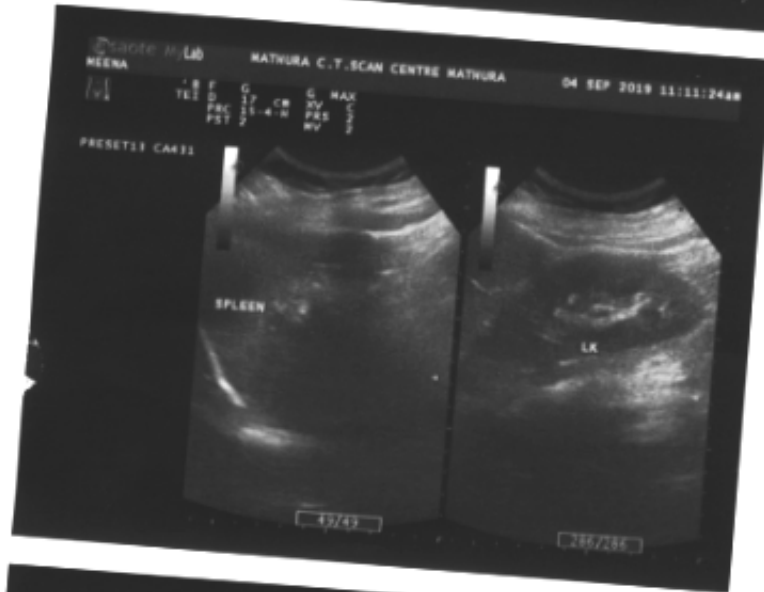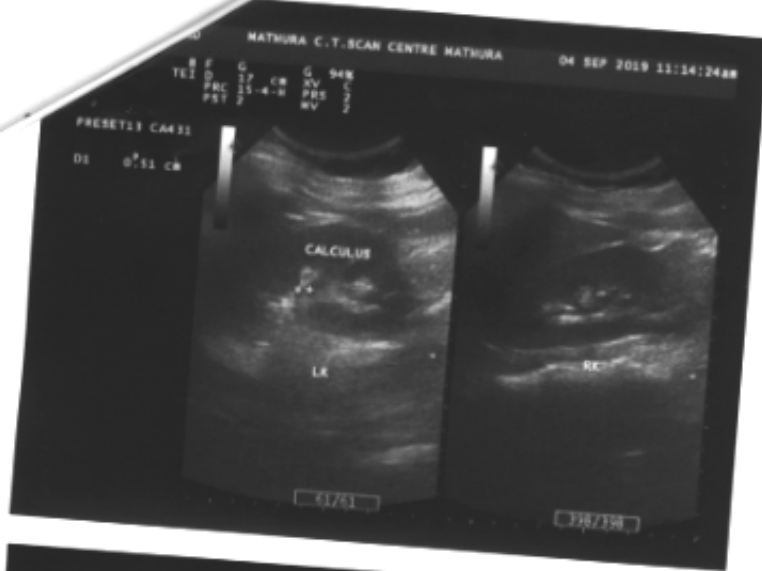■ Whole Body CT Scan ■ Echocardiography ■ Ultrasound ■ T.M.T. ■ Mammography ■ Color Doppler ■ Digital X-ray ■ Digital O.P.G. ■ E.E.G. ■ E.C.G. ■ Pathology

J. Scan Centre

Spiral CT Scan Digital X-ray, O.P.G., Mammography
ara (U.P.) Ph. 0565-2425480, 9267407990, 8938881688

Ex-Resident - J.N. Medical College, A.M.U., Aligarh
Ex-Consultant Radiologist - { Janta X-ray & Ultrasonics, Moradabad
Advanced Diagnostics, Amritsar
Kriti Scanning Centre, Allahabad

DATE: 04/09/19
AGE/SEX: 40Y/F



STUDY OF WHOLE ABDOMEN

echotexture. Margins are regular. Intrahepatic focal mass seen. Portal Vein is normal

pancreas shows normal wall thickness. No pericholecystic collection is seen. C.B.D.

gallbladder echotexture appears normal. No pericholecystic collection. No focal mass / peripancreatic

changes in size, shape and contour. Cortical echotexture. No calculus/hydronephrosis is seen.

RT. KIDNEY shows apx-5.1mm calculus in middle

calculus is seen. No hydronephrosis. Normal wall thickness. Lumen is clear. No

calculi (95.1x43.0x59.5mm) & shows apx-5.1mm lesion in posterior wall at body. Gallbladder appears normal. Echotexture.

NO HYDRONEPHROSIS. NO CALCULI.

DR. SUDHIR SINGH
CONSULTANT RADIOLOGIST

This is the professional opinion and not the diagnosis, based on imaging. It should be co-related clinically to arrive at conclusion. Best efforts were made during investigation, however in case of any Confusion/ Confirmation review can be done, free of cost. Not valid for medico-legal purpose.

THE NAME YOU TRUST.

नोट : रात्रि 11 बजे से प्रातः 5 बजे तक कार्य नहीं होता है।

Facilities :- Pulmonary Function Test (P.F.T.) Facility is also available

■ Whole Body CT Scan ■ Echocardiography ■ Ultrasound ■ T.M.T. ■ Mammography ■ Color Doppler ■ Digital X-ray ■ Digital O.P.G. ■ E.E.G. ■ E.C.G. ■ Pathology



दयालु हॉस्पिटल

नरहोली चौराहा, मथुरा

www.dayaluhospitalmathura.com dayaluhospital@gmail.com

MRS Meena Singh

Date: 18.09.18

Rx

Age - 43y 1F

9045302225

9415884425

DR Meena Singh

Clot Lucorshalee

- Vutuvacmibae

Rx

- Cap candiforce - 1BD (100)

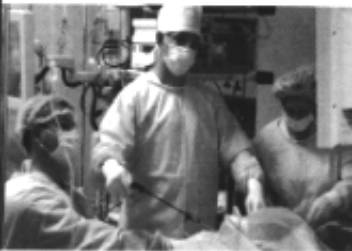- Gen wash - for wash (1)

- V Passorue candid v - 1/day 4S

- Omet Surper 5M - (1)

X 3day

Signature



सुविधायें

- सामान्य एवं दूरबीन सर्जरी
- हड्डी एवं जोड़ सर्जरी
- स्त्री एवं प्रसूति रोग
- फिजियोथैरेपी
- पैथोलॉजी
- मूत्र एवं गुदा रोग
- नेत्र रोग
- दन्त रोग
- एक्स-रे
- ई.सी.जी



NOT VALID FOR LEGAL OR MEDICO LEGAL PURPOSES