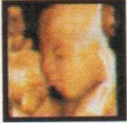



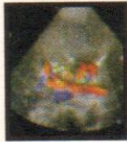
PATIENT'S NAME : Mrs. ARCHANA BHARTI
REF. BY : Dr.

DATE: 25.09.2014
AGE/SEX: /M



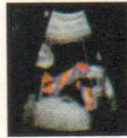U/S. WHOLE ABDOMEN

LIVER: Liver is normal in size, margins are smooth and parenchymal echoes normal. No focal abnormal echoes seen. Vascular pattern is normal. Intrahepatic biliary ductules are normal, non-dilated. Diaphragmatic movements are normal, not splinted.



GALL BLADDER: is normal in size, shape, outline and wall thickness. Lumen is clear. No calculus or mass lesion.


C.B.D.: is normal in width and clear lumen.



PANCREAS: is normal in size, shape, outline and echogenicity. No evidence of inflammatory disease or mass lesion.

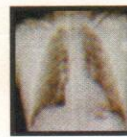KIDNEY-URETERIC UNITS: kidneys are slightly smaller in size, normal in shape, outline and central sinus echo complexes. No calculus, hydronephrosis or mass. Renal parenchymal echoes are enhanced with partial loss of cortico-medullary distinction. Ureters are non-dilated.

Rt.Kd.: 3.1x8.4 cm. Lt.Kd.: 3.0x8.8 cm. approx.

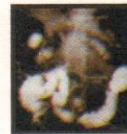

SPLEEN: is normal in size, capsular outline and echotexture. No abdominal lymphadenopathy, ascites or mass.

URI. BLADDER: is normal in size, shape, outline and position. Wall thickness is normal. No abnormal internal echoes seen. Rescanning after micturition shows residual urine volume in the range of 14cc as against pre void volume of 352cc.



UTERUS: is normal in size (3.6x4.1x10.0cm), shape with smooth serosal outline and well seen endometrial echo, which is 7.2mm thick as on today. No intrauterine mass or abnormal contents. Cervix is normal in size and echoes.



OVARIES: Bilateral ovaries are well seen and, left is normal in size and echotexture while in the right is ovary is noted a 2.5 x3.2mm size cyst with clear contents. No solid component or calcification.. No free fluid around it or elsewhere in follicle.

No sizeable pelvic mass or free fluid in P.O.D.



IMPRESSION: BILATERAL CHRONIC MEDICAL RENAL DISEASE GRADE II-III.

Clinico / biochemical correlation is suggested.

SMALL RIGHT OVARIAN CYST ? PHYSIOLOGICAL.

NO OTHER ABNORMAL OBSERVATIONS MADE.

AKHILESH SHARMA
MD