

From-

Om Pal Singh
Civil Judge(S.D.) F.T.C. Gautam Budh Nagar

To,

**Respected Assistant Registrar (Services)
Hon'ble High Court of Judicature at Allahabad.**

Through ,

Respected District Judge Gautam Budh Nagar

Subject - **Representation for over stay of one year at Gautam Budh Nagar due to ailment of my daughter Km. Chirakshi Singh age 6 years -**

Respected Sir,

With due respect I wish to submit that my transfer is due from District Gautam Budh Nagar on completion of normal tenure of three years.

With utmost regards I humbly wish to state that I have two children, one daughter Km. Chitrakshi Singh age 6 years and one son Master Kotesk Kumar age 3 years. My daughter Km. Chitrakshi Singh in suffering from **Multiple oval non-necrotic non calcified mesenteric lymph nodes in small bowel mesentery, short axis dimension measuring upto 6.7 mm and Bony mild dextrosciosis of dorsal spine** . She is unable to do her daily routine works without help and even cannot move properly due to spinal disorder . In August 2019 our family doctor advised us for her treatment at AIIMS New Delhi , where my daughter was found to be having **Multiple oval non-necrotic non calcified mesenteric lymph nodes in small bowel mesentery, short axis dimension measuring upto 6.7 mm and Bony mild dextrosciosis of dorsal spine** . Now my daughter is under treatment of AIIMS New Delhi, We are giving her medicines and behavioral therapy as per the advice of pediatric surgeons of AIIMS and as per their requirement of regular follow up we are visiting AIIMS New Delhi.

I humbly wish to submit that my wife Rashmi Singh is posted as P.G.T. (English) in Kendriya Vidyalaya Babugarh Cantt District Hapur 60 kms away from District Court Gautam Budh Nagar and my children are living there with my wife who being working lady is unable to manage our both small children, therefore in case of emergency I visit and take care my daughter and carry her for treatment at AIIMS New Delhi. For the proper treatment of my daughter, along with medicinal support she requires family support for recovery from ailment. Presently she is being cared by me and my wife. Moreover Delhi about 40 kms from Greater Noida and about 70 kms from Baubugarh Cantt District Hapur is in easy reach for regular consultation in AIIMS New Delhi in case of any emergency too it can be reached in just one & half hours.


By the collective efforts of medicines prescribed by Doctors of AIIMS New Delhi, me and My family my daughter is improving. Next year is very crucial for her treatment of disease. If I will be transferred to some other station my daughter's recovery from ailment will certainly be obstructed and her future will be affected adversely.

I, therefore very humbly request you to place my representation before the Hon'ble High Court of Judicature at Allahabad for kind and sympathetic consideration for over stay of one year at Gautam Budh Nagar.

With regards

Dated-27/11/2019

Yours Sincerely


(Om Pal Singh)
Civil Judge(S.D.) F.T.C.
Gautam Budh Nagar

Enclosure-

Medical papers of AIIMS Hospital New Delhi and
Medical reports of investigations



अ० भा० आ० सं० अस्पताल / A.I.I.M.S. HOSPITAL
बहिरंग रोगी विभाग / Out Patient Department

अस्पताल के अन्दर धूम्रपान मना है। / SMOKING IS PROHIBITED IN HOSPITAL PREMISES

शरीरमाद्यं चतुर्धर्मसामयम्

OPR-6

एकक/Unit _____

विभाग/Dept. _____

र०रो०वि० पंजीकृत सं०/O.P.D. Regn. No. _____

नाम/I

New Patient

Dept Reg. 2019/022/0005139

General/रु 10

PAED SURGERY/Paediatric Surgery OPD/Unit-I

कमरा/Room: 37

Name: Miss CHITRAKSHI

PS

D/O CM PAL

Days : Tuesday

6y महिला/F

Ph. 8126903549



UHID : 104686835

Date: 13/08/2019

पता/Address

निदान/Diagnosis:

Pain Abdomen

दिनांक/Date

उपचार/ Treatment

wt → 20kg

no pain in Abdomen X today

Similar episode - 3-4 months back

Stool → 3-4/dy

no recurrent vomiting

Urine → (NB)

fns - soft

no pain w/ passy stool

2 - non-specific -
22 - tubercular

Adx → - Hg, ESR, KFT, LFT

- DRG Chest

- CCT Abdomen
(to rule out CA)

2 - non-specific
Sup. Domitol 2-2-2

→ Sup. Duphalac 6-6-6

X 5 days

19/08/19 ESR - 32 mm/hr
H 4-11

[Signature]

Self attested

27/11/19

CLEAN AND GREEN AIIMS / एम्स का यही संकल्प, स्वच्छता से काया कल्प

अंगदान-जीवन का बहुमूल्य उपहार / ORGAN DONATION - A GIFT OF LIFE

O.R.B.O., AIIMS, 26588360, 26593444, www.orbo.org Helpline - 1060 (24 hrs service)

19/11/19

ESR ↑
C-reactive protein - small multiple (max 2.15)
16/11/19

water 200 -

DR - water 100 200
- Tol Rando Ave 1 stat
↓
Rep 2 week

Report
X.3 months

आहार - दैनिकीत

- 10kg wko
- 1 Kg Chan
- 50g S/O
- 300 ml
- 2000 mg

- diet -

- m 1 month

- m low

- फेला -
- अम्लक
- लोके (का) किले
- अंगूर -

- चकल - मग

- शाक - पुनट

100g - 200g - मरा पुनट
दोसा व लोका मसुर

20/11/19

low fat than
just for diet

water

- Sy, N3cc 6 ml OD
X 5dg
- Sabwan 250g TBS
x 2dg
- plenty of water

काले

Sy, N3cc 6 ml OD
6-6
X 3dg

self attested

27/11/19

21/11/19

DR - faalang, sandley
- filter water

- Sy, Neutrolin,
B
enlop

- m 1 month

low



FOCUS IMAGING & RESEARCH CENTRE PVT. LTD.

• NUCLEAR MEDICINE • DIAGNOSTIC RADIOLOGY • NON-INVASIVE CARDIOLOGY • NEURO-ELECTROPHYSIOLOGY • LABORATORY MEDICINE • PREVENTIVE HEALTHCARE

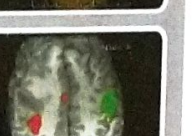
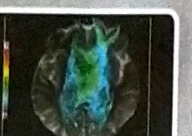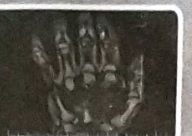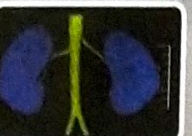


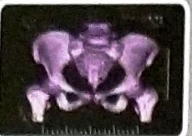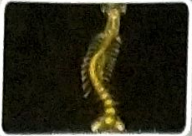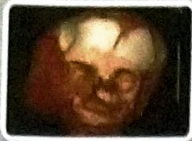ACCREDITED BY NABH FOR MEDICAL IMAGING SERVICES AS PER SCOPE



INTRODUCTION OF THE ALL NEW STATE OF ART PET-CT SUITE & SPECT GAMMA CAMERA

PET-CT SUITE / SPECT GAMMA CAMERA / MRI 3T / CARDIAC CT / 4D ULTRASOUND / COLOR DOPPLER / ECHO / TMT / DIGITAL X-RAY / MAMMOGRAPHY / BMD / EEG / EMG / NCV / VEP / ECG / LABORATORY MEDICINE



Permanent ID : P1079090

Registration No.: 101945014

Patient Name: Baby CHITRAKSHI

Age/Sex: 6 Yrs Female

ID Card No.:

Referred By: Dr. Paed Surgery

Referring Hosp.: AIIMS Hospital New Delhi



Mobile No 9457610125

Registration Dt./Tm.: 13/08/2019 14:08:12

Report Dt./Tm.: 16/08/2019 15:27:22

Validation Dt./Tm.: 16/08/2019 15:27:22

Printed Dt./Tm.: 20/08/2019 18:27:39

CT SCAN - WHOLE ABDOMEN

STUDY PROTOCOL:-

SECTIONS OF APPROPRIATE THICKNESS WERE DONE AT ADEQUATE INTERVALS IN STATE OF ART MULTI DETECTOR CT SCANNER (500SLICES/SEC) SO AS TO COVER THE ENTIRE REGION FROM DIAPHRAGMATIC DOMES TO THE PUBIC SYMPHYSIS AFTER THE ADMINISTRATION OF ORAL AND I.V. CONTRAST (NON-IONIC). FEW PLAIN CUTS WERE ALSO OBTAINED THROUGH THE REGION OF INTEREST. POST PROCESSING WAS DONE ON ADVANCE WORK STATION TO OBTAIN CORONAL SECTIONS.

CLINICAL INFORMATION:- Pain in abdomen since 10 days with recurrent vomiting, similar episode 3-4 months back. USG revealed hepatomegaly with bowel wall thickening and mesenteric lymph nodes.

FINDINGS:-

LIVER is normal in size with smooth contour and normal contrast enhancement. No focal mass lesion seen. Intra hepatic biliary radicals are normal.

Hepatic veins, IVC, portal vein and Splenoportal axis are patent.

Aorta and its mesenteric branches are patent.

GALLBLADDER is distended. No mass or calculus seen.

CBD is normal in course and calibre.

SPLEEN is normal in size and attenuation. No focal or diffuse lesion seen.

PANCREAS is normal in size and attenuation. No obvious calcifications seen. MPD is not dilated. Peripancreatic planes are preserved with no abnormal fat stranding or collection noted.

BOTH KIDNEYS are normal in size and attenuation. No calculus or hydronephrotic changes seen.

Bilateral supra renal glands are normal in size, shape and attenuation. No focal mass lesion seen.

URINARY BLADDER is normal in size and contour. No obvious calcification or mass lesion

"FOCUS... HEALTHCARE BEYOND IMAGINATION"

Corporate Office & Diagnostic Facilities:
Laboratory Medicine Hub:
Focus Helpline Numbers :

C-10, Green Park Extension, New Delhi-16 (MRI @ 3 Tesla, General Radiology Division)
H-10, Green Park Extension, New Delhi-16 (PET-CT, MRI @ 3 Tesla, General Radiology Division, Cardiac CT Scan)
7/1-4, Yusuf Sarai Market, Aurobindo Marg, New Delhi-16 (SPECT Gamma Camera & Laboratory Medicine Division)
+91 11 42199991 | +91 11 42199992 | +91 11 42199993 | +91 11 49490909

Website: www.focusimaging.co.in | E-mail: info@focusimaging.co.in
Focus Helpline Numbers for Laboratory Medicine Reports / Sample Collection queries : +91 11 42199999 • +91 9310683525 • +91 9310055365

ACCREDITED BY A.E.R.B. FOR RADIOLOGY SAFE PRACTICES

The Logo & Artwork including the Tag Line "FOCUS... HEALTHCARE BEYOND IMAGINATION" are Registered Trademarks of FOCUS IMAGING AND RESEARCH CENTRE PVT. LTD. Any Unauthorised Copying Duplication is liable for Legal Action. Clinical Correlation is essential for final diagnosis. If test results are unsatisfactory please contact personally. This report is for personal use of doctors only. Not for medico legal cases. All congenital anomalies in a foetus may not be diagnosed in routine obstetric ultrasound.

ON PANEL : CGHS, ESI, MCD, ECHS, DGEHS

AN ISO 9001 : 2015 CERTIFIED HEALTHCARE FACILITY

ACCREDITED BY NABL FOR LABORATORY MEDICINE SERVICES AS PER SCOPE

DOWNLOAD OUR MOBILE APP FROM GOOGLE PLAY STORE



Focus Helpline Numbers For PET-CT & SPECT Gamma Camera Appointments / Queries: +91 11 49490901 • +91 11 49490902 • +91 11 49490903 • +91 9873494949 • +91 9999816726 • +91 9310159916 • +91 9310683507/39/20 • +91 9810157570

Permanent ID :	P1079090		
Registration No.:	101945014	Mobile No.	9457610125
Patient Name:	Baby CHITRAKSHI	Registration Dt./Tm.:	13/08/2019 14:08:12
Age/Sex:	6 Yrs Female	Report Dt./Tm.:	16/08/2019 15:27:22
ID Card No.:		Validation Dt./Tm.:	16/08/2019 15:27:22
Referred By:	Dr. Paed Surgery	Printed Dt./Tm.:	20/08/2019 18:27:29
Referring Hosp.:	AIIMS Hospital New Delhi		

seen.

UTERUS is normal for age. No adnexal mass is seen on either side.

Visualized small and large bowel loops are normal.

Multiple oval non-necrotic non-calcified mesenteric lymph nodes are seen in small bowel mesentery, short axis dimension measuring upto ~ 6.7mm.

Visualized bones and joints are normal.


No retro peritoneal lymphadenopathy seen.


No free fluid is seen in the peritoneal cavity.

IMPRESSION:- CONTRAST CT SCAN ABDOMEN REVEALS:

- **Multiple oval non-necrotic non-calcified mesenteric lymph nodes in small bowel mesentery – infective etiology.**

ADVISE: CLINICAL CORRELATION AND FOLLOW-UP.

Self attested

 27/11/19


Dr. Trishita Laha
 MBBS, DNB (Radiodiagnosis)
 Associate Consultant Radiologist
 DMC Reg. No.: 56126



FOCUS IMAGING & RESEARCH CENTRE PVT. LTD.

• NUCLEAR MEDICINE • DIAGNOSTIC RADIOLOGY • NON-INVASIVE CARDIOLOGY • NEURO-ELECTROPHYSIOLOGY • LABORATORY MEDICINE • PREVENTIVE HEALTHCARE



ACCREDITED BY NABH FOR MEDICAL IMAGING SERVICES AS PER SCOPE



INTRODUCTION OF THE ALL NEW STATE OF ART PET-CT SUITE & SPECT GAMMA CAMERA

PET-CT SUITE / SPECT GAMMA CAMERA / MRI 3T / CARDIAC CT / 4D ULTRASOUND / COLOR DOPPLER / ECHO / TMT / DIGITAL X-RAY / MAMMOGRAPHY / BMD / EEG / EMG / NCV / VEP / ECG / LABORATORY MEDICINE

Permanent ID : P1079090

Registration No.: 101945014

Patient Name: Baby CHITRAKSHI

Age/Sex: 6 Yrs Female

ID Card No.:

Referred By: Dr. Paed Surgery

Referring Hosp.: AIIMS Hospital New Delhi

Mobile No.

9457610125

Registration Dt./Tm.: 13/08/2019 14:08:12

Report Dt./Tm.: 13/08/2019 16:51:49

Validation Dt./Tm.: 13/08/2019 16:51:50

Printed Dt./Tm.: 14/08/2019 13:41:20

DIGITAL X-RAY - CHEST PA

Bilateral lung fields are clear.

Trachea is central.

Cardiac size is normal.

Hila and mediastinum are unremarkable.

Both domes of diaphragm are normal.

Both cardiophrenic and costophrenic angles are normal.

Bony thoracic cage shows mild dextroscoliosis of dorsal spine.

ADVISED: CLINICAL CORRELATION.

Self attested
[Signature]
27/11/19

[Signature]

Dr. Trishita Laha
MBBS, DNB (Radiodiagnosis)
Associate Consultant Radiologist
DMC Reg. No.: 56126

"FOCUS... HEALTHCARE BEYOND IMAGINATION"

Corporate Office &
Diagnostic Facilities:
Laboratory Medicine Hub:
Focus Helpline Numbers :

C-10, Green Park Extension, New Delhi-16 (MRI @ 3 Tesla, General Radiology Division)
H-10, Green Park Extension, New Delhi-16 (PET-CT, MRI @ 3 Tesla, General Radiology Division, Cardiac CT Scan)
7/1-4, Yusuf Sarai Market, Aurobindo Marg, New Delhi-16 (SPECT Gamma Camera & Laboratory Medicine Division)
+91 11 42199991 | +91 11 42199992 | +91 11 42199993 | +91 11 49490909

Website: www.focusimaging.co.in | E-mail: info@focusimaging.co.in

Focus Helpline Numbers For Laboratory Medicine Reports / Sample Collection queries : +91 11 42199999 • +91 9310683525 • +91 9310055365

ACCREDITED BY A.E.R.B. FOR RADIOLOGY SAFE PRACTICES

The Logo & Artwork Including the Tag Line 'FOCUS... HEALTHCARE BEYOND IMAGINATION' are Registered Trademarks of FOCUS IMAGING AND RESEARCH CENTRE PVT. LTD. Any Unauthorised Copying/ Duplication is liable for Legal Action. This report is for perusal of doctors only. Not for medico-legal cases. All congenital anomalies in a foetus may not be diagnosed in routine obstetric ultrasound. Clinical Correlation is essential for final diagnosis. If test results are unsatisfactory, please contact personally.

ON PANEL : CGHS, ESI, MCD, ECHS, DGEHS

AN ISO 9001 : 2015 CERTIFIED HEALTHCARE FACILITY

ACCREDITED BY NABH FOR LABORATORY MEDICINE SERVICES AS PER SCOPE

Focus Helpline Numbers For PET-CT & SPECT Gamma Camera Appointments / Queries: +91 11 49490901 • +91 11 49490902 • +91 11 49490903

+91 9873494949 • +91 9999816726 • +91 9310159916 • +91 9310683507/39/20 • +91 9810157570

DOWNLOAD OUR MOBILE APP FROM GOOGLE PLAY STORE





FOCUS IMAGING & RESEARCH CENTRE PVT. LTD.[®]

• NUCLEAR MEDICINE • DIAGNOSTIC RADIOLOGY • NON-INVASIVE CARDIOLOGY • NEURO-ELECTROPHYSIOLOGY • LABORATORY MEDICINE • PREVENTIVE HEALTHCARE



NABH & NABL ACCREDITED FACILITY AS PER SCOPE



• CLINICAL HEMATOLOGY • CLINICAL PATHOLOGY • CLINICAL BIO-CHEMISTRY • CLINICAL MICRO-BIOLOGY

INTRODUCTION OF THE ALL NEW STATE OF ART PET-CT SUITE & SPECT GAMMA CAMERA

PET-CT SUITE / SPECT GAMMA CAMERA / MRI 3T / CARDIAC CT / 4D ULTRASOUND / COLOR DOPPLER / ECHO / TMT / DIGITAL X-RAY / MAMMOGRAPHY / BMD / EEG / EMG / NCV / YEP / ECG / LABORATORY MEDICINE

Permanent ID : P1079090 

Registration No.: 101945014 Mobile No. 9457610125

Patient Name: Baby CHITRAKSHI Registration Dt./Tm.: 13/08/2019 14:08:12

Age/Sex: 6 Yrs Female Sample Col. Dt./Tm.: 13/08/2019 14:19:51

ID Card No.: Sample Acc. Dt./Tm.: 13/08/2019 16:34:51

Referred By: Dr. Paed Surgery Report Dt./Tm.: 13/08/2019 18:44:24

Referring Hosp.: AIIMS Hospital New Delhi

Investigations

Result Biological Ref. Interval Units

Haematology

Complete Haemogram (CBC with ESR), Whole Blood EDTA

Haemoglobin (Hb) Whole Blood EDTA, Cyanmethaemoglobin Method	11.0	11.0 - 14.0	g/dL
RBC Count Whole Blood EDTA, Electrical Impedance	3.69	4.00 - 5.20	millions/cu.mm
PCV (Haematocrit) Whole Blood EDTA, Pulse Height Detection Method	32.6	34.0 - 40.0	%
MCV Whole Blood EDTA, Calculated	88.0	75.0 - 87.0	fL
MCH Whole Blood EDTA, Calculated	30.0	24.0 - 30.0	Picogram
MCHC Whole Blood EDTA, Calculated	33.9	31.0 - 37.0	gm/dL
TLC (Total Leukocyte Count) Whole Blood EDTA, Electrical Impedance	7.3	5.0 - 15.0	X10 ³ /uL

Differential Leukocyte Count (DLC)

Neutrophils Whole Blood EDTA, Microscopic	63	40 - 60	%
Lymphocytes Whole Blood EDTA, Microscopic	26	30 - 50	%
Eosinophils Whole Blood EDTA, Microscopic	01	01 - 06	%
Monocytes Whole Blood EDTA, Microscopic	10	02 - 08	%
Basophils Whole Blood EDTA, Microscopic	00	00 - 01	%
RDW-CV Whole Blood EDTA, Calculated	13.4	11.5 - 14.5	%
Platelet Count Whole Blood EDTA, Electric Impedance/Microscopy	202	200 - 490	X10 ³ /uL
ESR (Erythrocyte Sedimentation Rate) Whole Blood EDTA, OPTOELECTRONIC	32	00 - 20	mm/1st hr

Self affected
27/11/19

Page No: 1 of 4

"FOCUS... HEALTHCARE BEYOND IMAGINATION"[™]

Corporate Office & Diagnostic Facilities: C-10, Green Park Extension, New Delhi-16 (MRI @ 3 Tesla, General Radiology Division)
H-10, Green Park Extension, New Delhi-16 (PET-CT, MRI @ 3 Tesla, General Radiology Division, Cardiac CT Scan)
Laboratory Medicine Hub: 7/1-4, Yusuf Sarai Market, Aurobindo Marg, New Delhi-16 (SPECT Gamma Camera & Laboratory Medicine Division)
Focus Helpline Numbers: +91 11 42199991 | +91 11 42199992 | +91 11 42199993 | +91 11 49490909

Website: www.focusimaging.co.in | E-mail: info@focusimaging.co.in
Focus Helpline Numbers For Laboratory Medicine Reports / Sample Collection queries: • +91 11 42199999 • +91 9310683525 • +91 9310055365

ACCREDITED BY A.E.R.B. FOR RADIOLOGY SAFE PRACTICES

The Logo & Artwork including the Tag Line "FOCUS... HEALTHCARE BEYOND IMAGINATION" are Registered Trademarks of FOCUS IMAGING AND RESEARCH CENTRE PVT LTD. Any Unauthorised Copying/Duplication is liable for Legal Action.
• Clinical Correlation is essential for final diagnosis • If test results are unsatisfactory, please contact personally • This report is for personal use of doctors only • Not for Mass legal cases • All congenital anomalies in a foetus may not be diagnosed in routine obstetric ultrasound

ON PANEL: CGHS, ESI, MCD, ECHS, DGHES
AN ISO 9001 : 2015 CERTIFIED HEALTHCARE FACILITY
ACCREDITED BY NABH FOR MEDICAL IMAGING SERVICES AS PER SCOPE
Tests Marked With * Are Not Covered in NABL Scope.

DOWNLOAD OUR MOBILE APP FROM GOOGLE PLAY STORE



Focus Helpline Numbers For PET-CT & SPECT Gamma Camera Appointments / Queries: • +91 11 49490901 • +91 11 49490902 • +91 11 49490903
• +91 9873494949 • +91 9999816726 • +91 9310159916 • +91 9310683507/39/20 • +91 9810157570



Permanent ID : P1079090
Registration No.: 101945014
Patient Name: Baby CHITRAKSHI
Age/Sex: 6 Yrs Female
ID Card No.:
Referred By: Dr. Paed Surgery
Referring Hosp.: AIIMS Hospital New Delhi

Mobile No. 9457610125
Registration Dt./Tm.: 13/08/2019 14:08:12
Sample Col. Dt./Tm.: 13/08/2019 14:19:51
Sample Acc. Dt./Tm.: 13/08/2019 16:34:53
Report Dt./Tm.: 13/08/2019 18:44:24



Investigations

Result Biological Ref. Interval Units

Dr. Sudhir Vatsa
MBBS, MD (Pathology)
Senior Consultant Pathologist
DMC Reg No. 32570
Dr. Asif Baliyan

Self attached

27/11/19



FOCUS IMAGING & RESEARCH CENTRE PVT. LTD.

• NUCLEAR MEDICINE • DIAGNOSTIC RADIOLOGY • NON-INVASIVE CARDIOLOGY • NEURO-ELECTROPHYSIOLOGY • LABORATORY MEDICINE • PREVENTIVE HEALTHCARE



NABH & NABL ACCREDITED FACILITY AS PER SCOPE



• CLINICAL HEMATOLOGY • CLINICAL PATHOLOGY • CLINICAL BIO-CHEMISTRY • CLINICAL MICRO-BIOLOGY

INTRODUCTION OF THE ALL NEW STATE OF ART PET-CT SUITE & SPECT GAMMA CAMERA

PET-CT SUITE / SPECT GAMMA CAMERA / MRI 3T / CARDIAC CT / 4D ULTRASOUND / COLOR DOPPLER / ECHO / TMT / DIGITAL X-RAY / MAMMOGRAPHY / BMD / EEG / EMG / NCV / VEP / ECG / LABORATORY MEDICINE

Permanent ID :	P1079090		
Registration No.:	101945014	Mobile No.	9457610125
Patient Name:	Baby CHITRAKSHI	Registration Dt./Tm.:	13/08/2019 14:08:12
Age/Sex:	6 Yrs Female	Sample Col. Dt./Tm.:	13/08/2019 15:18:53
ID Card No.:		Sample Acc. Dt./Tm.:	13/08/2019 16:34:51
Referred By:	Dr. Paed Surgery	Report Dt./Tm.:	13/08/2019 18:26:42
Referring Hosp.:	AIIMS Hospital New Delhi		

Investigations	Result	Biological Ref. Interval	Units
----------------	--------	--------------------------	-------

Biochemistry

Liver Function Test (LFT)

Total Protein, Serum <small>Serum, Buret</small>	6.0	6.6 - 8.3	g/dl
Albumin Serum <small>Serum, Bromocresol green</small>	4.14	3.50 - 5.20	gm/dL
Globulin, Serum <small>Serum, Calculated</small>	1.9	2.3 - 3.5	gm/dL
A:G (Albumin:Globulin) Ratio <small>Serum, Calculated</small>	2.18	1.50 - 2.50	
SGOT/AST (Aspartate Amino-transferase) <small>Serum, IFCC Without P-S-P</small>	36.0	0.0 - 35.0	IU/L
SGPT/ALT (Alanine Amino-transferase) <small>Serum, IFCC Without P-S-P</small>	13.0	0.0 - 35.0	IU/L
ALP (Alkaline Phosphatase) <small>Serum, Kinetic, IFCC</small>	176.0	54.0 - 369.0	U/L
GGTP (Gamma Glutamyl-transpeptidase) <small>Serum, IFCC</small>	11	7 - 32	IU/L
Bilirubin, Total, Serum <small>Serum, DPD</small>	0.3	0.3 - 1.2	mg/dL
Bilirubin, Direct, Serum <small>Serum, DPD</small>	0.08	0.00 - 0.20	mg/dL
Bilirubin, Indirect, Serum <small>Serum, Calculated</small>	0.22	0.10 - 0.50	mg/dL

Self attested
[Signature]
27/11/19

[Signature]

Dr. Asif Baliyan
MBBS, MD (Pathology)
Consultant Pathologist
DMC Reg No.: 60527

Page No: 3 of 4

"FOCUS... HEALTHCARE BEYOND IMAGINATION"

Corporate Office & Diagnostic Facilities: C-10, Green Park Extension, New Delhi-16 (MRI @ 3 Tesla, General Radiology Division)
 Laboratory Medicine Hub: H-10, Green Park Extension, New Delhi-16 (PET-CT, MRI @ 3 Tesla, General Radiology Division, Cardiac CT Scan)
 Focus Helpline Numbers: 7/1-4, Yusuf Sarai Market, Aurobindo Marg, New Delhi-16 (SPECT Gamma Camera & Laboratory Medicine Division)
 +91 11 42199991 | +91 11 42199992 | +91 11 42199993 | +91 11 49490909

Website: www.focusimaging.co.in | E-mail: info@focusimaging.co.in
 Focus Helpline Numbers For Laboratory Medicine Reports / Sample Collection queries: +91 11 42199999 • +91 9310683525 • +91 9310055365

ACCREDITED BY A.E.R.B. FOR RADIOLOGY SAFE PRACTICES



Including the Tag Line "FOCUS... HEALTHCARE BEYOND IMAGINATION" are Registered Trademarks of FOCUS IMAGING AND RESEARCH CENTRE PVT. LTD. Any Unauthorised Copying/ Duplication is liable for Legal Action

• Clinical Correlation is essential for final diagnosis • If test results are unsatisfactory, please contact personally. • This report is for personal use of doctors only. • Not for medico-legal cases. • All congenital anomalies in a foetus may not be diagnosed in routine obstetric ultrasound.



AN ISO 9001 : 2015 CERTIFIED HEALTHCARE FACILITY



ACCREDITED BY NABH FOR MEDICAL IMAGING SERVICES AS PER SCOPE


Tests Marked With * Are Not Covered in NABL Scope.

DOWNLOAD OUR MOBILE APP FROM GOOGLE PLAY STORE



Focus Helpline Numbers For PET-CT & SPECT Gamma Camera Appointments / Queries: +91 11 49490901 • +91 11 49490902 • +91 11 49490903
 • +91 9873494949 • +91 9999816726 • +91 9310159916 • +91 9310683507/39/20 • +91 9810157570


Permanent ID : P1079090
Registration No.: 101945014
Patient Name: Baby CHITRAKSHI
Age/Sex: 6 Yrs Female
ID Card No.:
Referred By: Dr. Paed Surgery
Referring Hosp.: AIIMS Hospital New Delhi


Mobile No. 9457610125
Registration Dt./Tm.: 13/08/2019 14:08:12
Sample Col. Dt./Tm.: 13/08/2019 15:18:53
Sample Acc. Dt./Tm.: 13/08/2019 16:34:51
Report Dt./Tm.: 13/08/2019 18:26:42

<u>Investigations</u>	<u>Result</u>	<u>Biological Ref. Interval</u>	<u>Units</u>
-----------------------	---------------	---------------------------------	--------------

Kidney Function Test (KFT)

Urea, Serum <small>Serum, Urease-Glutamate Dehydrogenase</small>	17	17 - 43	mg/dL
Creatinine, Serum <small>Serum, Jaffes</small>	0.50	0.55 - 1.20	mg/dL
Uric Acid, Serum <small>Serum, Uricase</small>	4.33	2.60 - 6.00	mg/dL
Sodium, Serum <small>Serum, Ion Selective Electrode</small>	141	136 - 145	mEq/L
Potassium, Serum <small>Serum, Ion Selective Electrode</small>	4.3	3.5 - 5.5	mEq/L
Chloride Serum <small>Serum, Ion Selective Electrode</small>	99	95 - 107	mEq/L
Phosphorus, Serum <small>Serum, Direct Phosphomolybdate</small>	3.3	2.5 - 4.5	mg/dL
Calcium, Serum <small>Serum, Arsenazo III</small>	9.2	8.8 - 10.6	mg/dL



Dr. Asif Baliyan
MBBS, MD (Pathology)
Consultant Pathologist
DMC Reg No.: 60527



सोमती नर्सिंग होम

डा० सोमती केन

MBBS, DGO (KGMC) IFUMB

प्रसूति एवं स्त्री रोग विशेषज्ञ एवं सर्जन

डा० नरेन्द्र केन

MBBS., D.M.R.D., I.F.U.M.B., M.I.R.I.A.

अल्ट्रासोनोलोजिस्ट एवं रेडियोलोजिस्ट

Dated.....

Pt's Name	Chitrakshi	Age/ Sex	5Y / F
Under Care of	SELF		10 August 2019

USG WHOLE ABDOMEN

LIVER - mildly enlarged in size. Shape is maintained. Echogenicity of liver maintained. No echovariant lesion seen in liver parenchyma .no IHBRD seen.

Caudate lobe normal. Diameter of hepatic vein maintained.

GALL BLADDER distended in size .no stone seen in lumen of GB.

CBD AND PV - normal in course and caliber.

PANCREAS - normal in size and shape. Pancreatic duct not dilated.

SPLEEN - normal in size and shape. Echogenicity of spleen maintained.

No echo variant lesion seen in splenic parenchyma.

BOTH KIDNEYS - normal in size and shape .no hydronephrosis present in both kidneys

CM differentiation maintained on both side. Perirenal spaces is clear. Parenchymal

thickness maintained on both side. Surface of both kidneys regular.

BOTH URETERS - not dilated,

URINARY BLADDER - distended

UTERUS normal in size and shape

No free fluid seen in b/l pleural and peritoneal cavity.

OPINION.

Mild hepatomegaly present . bowel wall thick irregular and edematous .

Multiple 12-14 mm mesnetric lymph nodes present

ADV BLOOD EXAMINTION WITH LFT/ALP/ ESR

PLEASE CORELATE CLINICALLY.

Self attested
27/11/19

DR NARENDER KAIN

MBBS DMRD MIRIA IFUMB

RADIOLOGIST

(प्रत्येक रविवार साँय की OPD बन्द रहेगी)

CT-SCAN की सुविधा 24 घन्टे उपलब्ध है।


कवि नगर, गढ़ चुंगी, गढ़ रोड, हापुड़, Ph : No. 0122-2334455, 9837085256

समय : सुबह 10.00 बजे से 2.00 बजे तक
सायं 6.00 बजे से 8.00 बजे तक

मेडिकोलीगल उपयोग
के लिए नहीं

रंगीन अल्ट्रासाउण्ड की विशेष
सुविधा उपलब्ध है।

जापान की अत्याधुनिक व हापुड़ की सबसे बड़ी एक्सरे मशीन के द्वारा एक्सरे की सुविधा



Self attested
[Signature]
27/11/19




भारतीय विशिष्ट पहचान प्राधिकरण
भारत सरकार
Unique Identification Authority of India
Government of India

नामांकन क्रम/ Enrolment No.: 2189/53998/00023

To
चित्राक्षी सिंह
Chitrakshi Singh
D/O: Ompal Singh
ward no 14
naya bans
Bakhtawarpur
Garh Bridge Halt
Hapur Uttar Pradesh - 245205
9634340549

Download Date: 17/05/2018
Generation Date: 08/08/2017

Signature Not Verified
Digitally signed by Chitrakshi Singh
Unique Identification Authority of India
DN: cn=Chitrakshi Singh, o=UIDAI



QR Code with Photograph

आपका आधार क्रमांक / Your Aadhaar No. :

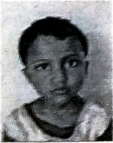9707 9832 3448

VID : 9154 3048 5402 7952

मेरा आधार, मेरी पहचान



भारत सरकार
Government of India



चित्राक्षी सिंह
Chitrakshi Singh
जन्म तिथि/DOB: 15/11/2013
लिंग/FEMALE

9707 9832 3448

VID : 9154 3048 5402 7952

मेरा आधार, मेरी पहचान



Government of India



सूचना

- आधार पहचान का प्रमाण है, नागरिकता का नहीं।
- पहचान का प्रमाण ऑनलाइन ऑथेंटिकेशन द्वारा प्राप्त करें।
- यह एक इलेक्ट्रॉनिक प्रक्रिया द्वारा बना हुआ पत्र है।

नोट: बच्चे 15 वर्ष की उम्र होने पर बायोमेट्रिक विशिष्टताओं का नवीनीकरण कराएँ।

INFORMATION

- Aadhaar is a proof of identity, not of citizenship.
- To establish identity, authenticate online.
- This is electronically generated letter.

Note: Children on attaining 15 years of age need to update biometric information.


- आधार देश भर में मान्य है।
- आधार भविष्य में सरकारी और गैर-सरकारी सेवाओं का लाभ उठाने में उपयोगी होगा।
- Aadhaar is valid throughout the country.
- Aadhaar will be helpful in availing Government and Non-Government services in future.



भारतीय विशिष्ट पहचान प्राधिकरण
Unique Identification Authority of India

पता:
आम्पला: ओम्पाल सिंह, वॉर्ड न 14, नया बांस, बख्तावरपुर,
हपुड़,
उत्तर प्रदेश - 245205

Address:
D/O: Ompal Singh, ward no 14, naya bans,
Bakhtawarpur, Hapur,
Uttar Pradesh - 245205



QR Code with Photograph

9707 9832 3448

VID : 9154 3048 5402 7952

1947
http://unaid.gov.in

www.uidai.gov.in

Self attested
22/11/19