

2017  
28/11/19

From-

Om Pal Singh  
Civil Judge(S.D.) F.T.C. Gautam Budh Nagar

To,

Respected Assistant Registrar (Services)  
Hon'ble High Court of Judicature at Allahabad.

Through ,

Respected District Judge Gautam Budh Nagar

Subject – Representation for over stay of one year at Gautam Budh Nagar due to ailment of my daughter Km. Chirakshi Singh age 6 years -

Respected Sir,

With due respect I wish to submit that my transfer is due from District Gautam Budh Nagar on completion of normal tenure of three years.

With utmost regards I humbly wish to state that I have two children, one daughter Km. Chitrakshi Singh age 6 years and one son Master Kotesch Kumar age 3 years. My daughter Km. Chitrakshi Singh in suffering from **Multiple oval non-necrotic non calcified mesenteric lymph nodes in small bowel mesentery, short axis dimension measuring upto 6.7 mm and Bony mild dextroscoliosis of dorsal spine** . She is unable to do her daily routine works without help and even cannot move properly due to spinal disorder . In August 2019 our family doctor advised us for her treatment at AIIMS New Delhi , where my daughter was found to be having **Multiple oval non-necrotic non calcified mesenteric lymph nodes in small bowel mesentery, short axis dimension measuring upto 6.7 mm and Bony mild dextroscoliosis of dorsal spine** . Now my daughter is under treatment of AIIMS New Delhi, We are giving her medicines and behavioral therapy as per the advice of pediatric surgeons of AIIMS and as per their requirement of regular follow up we are visiting AIIMS New Delhi.

I humbly wish to submit that my wife Rashmi Singh is posted as P.G.T. (English) in Kendriya Vidyalaya Babugarh Cantt District Hapur 60 kms away from District Court Gautam Budh Nagar and my children are living there with my wife who being working lady is unable to manage our both small children, therefore in case of emergency I visit and take care my daughter and carry her for treatment at AIIMS New Delhi. For the proper treatment of my daughter, along with medicinal support she requires family support for recovery from ailment. Presently she is being cared by me and my wife. Moreover Delhi about 40 kms from Greater Noida and about 70 kms from Baubugarh Cantt District Hapur is in easy reach for regular consultation in AIIMS New Delhi in case of any emergency too it can be reached in just one & half hours.


By the collective efforts of medicines prescribed by Doctors of AIIMS New Delhi, me and My family my daughter is improving. Next year is very crucial for her treatment of disease. If I will be transferred to some other station my daughter's recovery from ailment will certainly be obstructed and her future will be affected adversely.

I, therefore very humbly request you to place my representation before the Hon'ble High Court of Judicature at Allahabad for kind and sympathetic consideration for over stay of one year at Gautam Budh Nagar.

With regards

Dated-28/11/2019

Yours Sincerely



(Om Pal Singh)

Civil Judge(S.D.) F.T.C.

Gautam Budh Nagar

सिपित जज (सी.डी.)/F.T.C.  
गौतमबुधनगर

Enclosure-

Medical papers of AIIMS Hospital New Delhi and  
Medical reports of investigations


Office of District Judge, Gautam Budh Nagar

Letter No.- /Admin / Gautam Budh Nagar/ Dated

Forwarded to Hon'ble High Court of Judicature at Allahabad for kind consideration.

Endorsment No. 1879/XV/D:28/11/19  
Forwarded to Respected Assistant Registrar (Services),  
Hon'ble High Court of Judicature at Allahabad.

District and Sessions Judge  
Gautam Budh Nagar

  
District Judge  
Gautam Budh Nagar  
25/11/19



अ० भा० आ० सं० अस्पताल / A.I.I.M.S. HOSPITAL  
बहिरंग रोगी विभाग / Out Patient Department

अस्पताल के अन्दर धूम्रपान मना है / SMOKING IS PROHIBITED IN HOSPITAL PREMISES

शरीरवाचं खलु धर्मसाधनम्

OPR-6

एकक/Unit \_\_\_\_\_

विभाग/Dept. \_\_\_\_\_

ब०रो०वि० पंजीकृत सं०/O.P.D. Regn. No. \_\_\_\_\_

नाम/1

New Patient

Dept Reg. 2019/022/0005139

General/र 10

PAED SURGERY/Paediatric Surgery OPD/Unit-I

कमरा/Room: 37

Name: Miss CHITRAKSHI

PS

Days : Tuesday

D/O OM PAL

6Y महिला/F

Ph. 8126903549



UHID : 104686835

Date: 13/08/2019

पता/Address

Pain Abdomen

निदान/Diagnosis:

दिनांक/Date

उपचार/Treatment

wt → 20kg

no pain in Abdomen X today

Similar episode - 3-4 months back

Stool → 3-4/day

no recurrent weight loss

Urine → (NB)

FM - soft

no pain w/ passy stool

2 - nonspecific -

?? Tubercular

Adx → - Hg, ESR, KFT, LFT

- CXR Chest

- CECT Abdomen  
(Tubercular case)

इन्फेक्शियस

Exp. Domitol 2-2-2

→ Exp. Duphalac 6-6-6

X today

19/08/19 ESR - 32 mm/hr

H 4-11

Self at home

27/11/19

CLEAN AND GREEN AIIMS / एम्स का यही संकल्प, स्वच्छता से काया कल्प

अंगदान-जीवन का बहुमूल्य उपहार / ORGAN DONATION - A GIFT OF LIFE

O.R.B.O., AIIMS, 26588360, 26593444, www.orbo.org Helpline - 1060 (24 hrs service)

19/11/19

ESRT  
C-1000 - small multiple man 211  
(17/11)

water 200 -

sdh - water 100 200

- Tol Randy for 1 stat  
↓  
Repat 2200 | Repat  
X 3 more

आटा - हनुमन्त

- 10kg wko
- 1 Kg cham
- 50g sp.
- 300 ml
- 2000 kg.

- diet -

- As 1 month

- sdh

- फेना -
- सप्तर्षि
- लोके (वि) विने
- अंगूर -

- च (को) - फल

- शाक - पुस्त

1000-2000 - ग्रा 2 2 0  
हनुमन्त व लोके गपक

21/11/19

sdh - faaloy, sandier

- filter water.

- Sy, Neutrolon,  
B  
5ml op

- As 1 month

sdh

28/11/19

low for travel  
good for diet

w/kg

- Sy, 13cc 6 ml OD.
- X 5dg
- 250g 250g Tbs
- X 2dg
- plenty of water

सप्तर्षि Sy, v's, codyn 6-6

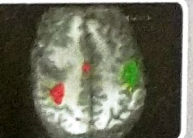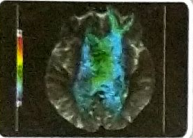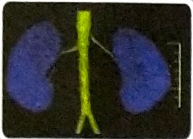
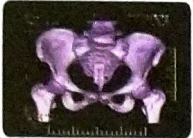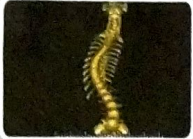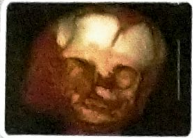self attested

27/11/19



## INTRODUCTION OF THE ALL NEW STATE OF ART PET-CT SUITE & SPECT GAMMA CAMERA

PET-CT SUITE / SPECT GAMMA CAMERA / MRI 3T / CARDIAC CT / 4D ULTRASOUND / COLOR DOPPLER / ECHO / TMT / DIGITAL X-RAY / MAMMOGRAPHY / BMD / EEG / EMG / NCV / VEP / ECG / LABORATORY MEDICINE



Permanent ID : P1079090

Registration No.: 101945014

Patient Name: Baby CHITRAKSHI

Age/Sex: 6 Yrs Female

ID Card No.:

Referred By: Dr. Paed Surgery

Referring Hosp.: AIIMS Hospital New Delhi



Mobile No. 9457610125

Registration Dt./Tm.: 13/08/2019 14:08:12

Report Dt./Tm.: 16/08/2019 15:27:22

Validation Dt./Tm.: 16/08/2019 15:27:22

Printed Dt./Tm.: 20/08/2019 18:27:39

### CT SCAN - WHOLE ABDOMEN

#### STUDY PROTOCOL:-

SECTIONS OF APPROPRIATE THICKNESS WERE DONE AT ADEQUATE INTERVALS IN STATE OF ART MULTI DETECTOR CT SCANNER (500SLICES/SEC) SO AS TO COVER THE ENTIRE REGION FROM DIAPHRAGMATIC DOMES TO THE PUBIC SYMPHYSIS AFTER THE ADMINISTRATION OF ORAL AND I.V. CONTRAST (NON-IONIC). FEW PLAIN CUTS WERE ALSO OBTAINED THROUGH THE REGION OF INTEREST. POST PROCESSING WAS DONE ON ADVANCE WORK STATION TO OBTAIN CORONAL SECTIONS.

**CLINICAL INFORMATION:-** Pain in abdomen since 10 days with recurrent vomiting, similar episode 3-4 months back. USG revealed hepatomegaly with bowel wall thickening and mesenteric lymph nodes.

#### FINDINGS:-

**LIVER** is normal in size with smooth contour and normal contrast enhancement. No focal mass lesion seen. Intra hepatic biliary radicals are normal.

Hepatic veins, IVC, portal vein and Splenoportal axis are patent.

Aorta and its mesenteric branches are patent.

**GALLBLADDER** is distended. No mass or calculus seen.

**CBD** is normal in course and calibre.

**SPLEEN** is normal in size and attenuation. No focal or diffuse lesion seen.

**PANCREAS** is normal in size and attenuation. No obvious calcifications seen. MPD is not dilated. Peripancreatic planes are preserved with no abnormal fat stranding or collection noted.

**BOTH KIDNEYS** are normal in size and attenuation. No calculus or hydronephrotic changes seen.

Bilateral supra renal glands are normal in size, shape and attenuation. No focal mass lesion seen.

**URINARY BLADDER** is normal in size and contour. No obvious calcification or mass lesion

*Self attested*  
*[Signature]*  
*27/11/19*

### "FOCUS... HEALTHCARE BEYOND IMAGINATION"®

Corporate Office & Diagnostic Facilities:  
Laboratory Medicine Hub:  
Focus Helpline Numbers :

C-10, Green Park Extension, New Delhi-16 (MRI @ 3 Tesla, General Radiology Division)  
H-10, Green Park Extension, New Delhi-16 (PET-CT, MRI @ 3 Tesla, General Radiology Division, Cardiac CT Scan)  
7/1-4, Yusuf Sarai Market, Aurobindo Marg, New Delhi-16 (SPECT Gamma Camera & Laboratory Medicine Division)  
+91 11 42199991 | +91 11 42199992 | +91 11 42199993 | +91 11 49490909

Website: www.focusimaging.co.in | E-mail: info@focusimaging.co.in

Focus Helpline Numbers For Laboratory Medicine Reports / Sample Collection queries : +91 11 42199999 • +91 9310683525 • +91 9310055365

**ACCREDITED BY A.E.R.B. FOR RADIOLOGY SAFE PRACTICES**



Including the Tag Line 'FOCUS - HEALTHCARE BEYOND IMAGINATION' are Registered Trademarks of FOCUS IMAGING AND RESEARCH CENTRE PVT LTD. Any Unauthorised Copying/ Duplication is liable for Legal Action

Clinical Correlation is essential for final diagnosis. If test results are unsatisfactory, please contact personally. This report is for perusal of doctors only. Not for medico legal cases. All congenital anomalies in a foetus may not be diagnosed in routine obstetric ultrasound.

**ON PANEL : CGHS, ESI, MCD, ECHS, DGEHS**




**AN ISO 9001 : 2015 CERTIFIED HEALTHCARE FACILITY**



ACCREDITED BY NABL FOR LABORATORY MEDICINE SERVICES AS PER SCOPE

DOWNLOAD OUR MOBILE APP FROM GOOGLE PLAY STORE



Permanent ID :	P1079090		
<b>Registration No.:</b>	<b>101945014</b>	Mobile No.	9457610125
Patient Name:	Baby CHITRAKSHI	Registration Dt./Tm.:	13/08/2019 14:08:12
Age/Sex:	6 Yrs Female	Report Dt./Tm.:	16/08/2019 15:27:22
ID Card No.:		Validation Dt./Tm.:	16/08/2019 15:27:22
Referred By:	Dr. Paed Surgery	Printed Dt./Tm.:	26/08/2019 18:47:39
Referring Hosp.:	AIIMS Hospital New Delhi		

seen.

**UTERUS** is normal for age. No adnexal mass is seen on either side.

Visualized small and large bowel loops are normal.

**Multiple oval non-necrotic non-calcified mesenteric lymph nodes are seen in small bowel mesentery, short axis dimension measuring upto ~ 6.7mm.**

Visualized bones and joints are normal.


No retro peritoneal lymphadenopathy seen.


No free fluid is seen in the peritoneal cavity.


**IMPRESSION:- CONTRAST CT SCAN ABDOMEN REVEALS:**

- **Multiple oval non-necrotic non-calcified mesenteric lymph nodes in small bowel mesentery – infective etiology.**

**ADVISE: CLINICAL CORRELATION AND FOLLOW-UP.**

Self attested  
  
 27/11/19

  
**Dr. Trishita Laha**  
 MBBS, DNB (Radiodiagnosis)  
 Associate Consultant Radiologist  
 DMC Reg. No.: 56126



# FOCUS IMAGING & RESEARCH CENTRE PVT. LTD.

• NUCLEAR MEDICINE • DIAGNOSTIC RADIOLOGY • NON-INVASIVE CARDIOLOGY • NEURO-ELECTROPHYSIOLOGY • LABORATORY MEDICINE • PREVENTIVE HEALTHCARE

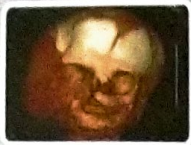

ACCREDITED BY NABH FOR MEDICAL IMAGING SERVICES AS PER SCOPE



## INTRODUCTION OF THE ALL NEW STATE OF ART PET-CT SUITE & SPECT GAMMA CAMERA

PET-CT SUITE / SPECT GAMMA CAMERA / MRI 3T / CARDIAC CT / 4D ULTRASOUND / COLOR DOPPLER / ECHO / TMT / DIGITAL X-RAY / MAMMOGRAPHY / BMD / EEG / EMG / NCV / VEP / ECG / LABORATORY MEDICINE



Permanent ID : P1079090



Registration No.: 101945014

Mobile No. 9457610125

Patient Name: Baby CHITRAKSHI

Registration Dt./Tm.: 13/08/2019 14:08:12

Age/Sex: 6 Yrs Female

Report Dt./Tm.: 13/08/2019 16:51:49

ID Card No.:

Validation Dt./Tm.: 13/08/2019 16:51:50

Referred By: Dr. Paed Surgery

Printed Dt./Tm.: 14/08/2019 13:41:20

Referring Hosp.: AIIMS Hospital New Delhi

### DIGITAL X-RAY - CHEST PA

Bilateral lung fields are clear.

Trachea is central.

Cardiac size is normal.

Hila and mediastinum are unremarkable.

Both domes of diaphragm are normal.

Both cardiophrenic and costophrenic angles are normal.

**Bony thoracic cage shows mild dextroscoliosis of dorsal spine.**

### ADVISED: CLINICAL CORRELATION.

*Self attested*  
*[Signature]*  
*27/8/19*

*[Signature]*  
**Dr. Trishita Laha**

MBBS, DNB (Radiodiagnosis)  
Associate Consultant Radiologist  
DMC Reg. No.: 56126

### "FOCUS... HEALTHCARE BEYOND IMAGINATION"<sup>™</sup>

Corporate Office &  
Diagnostic Facilities:  
Laboratory Medicine Hub:  
Focus Helpline Numbers :

C-10, Green Park Extension, New Delhi-16 (MRI @ 3 Tesla, General Radiology Division)  
H-10, Green Park Extension, New Delhi-16 (PET-CT, MRI @ 3 Tesla, General Radiology Division, Cardiac CT Scan)  
7/1-4, Yusuf Sarai Market, Aurobindo Marg, New Delhi-16 (SPECT Gamma Camera & Laboratory Medicine Division)  
+91 11 42199991 | +91 11 42199992 | +91 11 42199993 | +91 11 49490909

Website: [www.focusimaging.co.in](http://www.focusimaging.co.in) | E-mail: [info@focusimaging.co.in](mailto:info@focusimaging.co.in)  
Focus Helpline Numbers For Laboratory Medicine Reports / Sample Collection queries : +91 11 42199999 • +91 9310683525 • +91 9310055365

**ACCREDITED BY A.E.R.B. FOR RADIOLOGY SAFE PRACTICES**

The Logo & Emblem including the Tag Line 'FOCUS. HEALTHCARE BEYOND IMAGINATION' are Registered Trademarks of FOCUS IMAGING AND RESEARCH CENTRE PVT. LTD. Any Unauthorised Copying/ Duplication is liable for Legal Action.  
Clinical Correlation is essential for final diagnosis. If test results are unsatisfactory please contact personally. This report is for personal of doctors only. Not for medico legal cases. All congenital anomalies in a foetus may not be diagnosed in routine obstetric ultrasound.

**ON PANEL : CGHS, ESI, MCD, ECHS, DGEHS**



**AN ISO 9001 : 2015 CERTIFIED HEALTHCARE FACILITY**



ACCREDITED BY NABL FOR LABORATORY MEDICINE SERVICES AS PER SCOPE

DOWNLOAD OUR MOBILE APP FROM GOOGLE PLAY STORE



Focus Helpline Numbers For PET-CT & SPECT Gamma Camera Appointments / Queries: +91 11 49490901 • +91 11 49490902 • +91 11 49490903

+91 9873494949 • +91 9999816726 • +91 9310159916 • +91 9310683507/39/20 • +91 9810157570



# FOCUS IMAGING & RESEARCH CENTRE PVT. LTD.

• NUCLEAR MEDICINE • DIAGNOSTIC RADIOLOGY • NON-INVASIVE CARDIOLOGY • NEURO-ELECTROPHYSIOLOGY • LABORATORY MEDICINE • PREVENTIVE HEALTHCARE



NABH & NABL ACCREDITED FACILITY AS PER SCOPE



• CLINICAL HEMATOLOGY • CLINICAL PATHOLOGY • CLINICAL BIO-CHEMISTRY • CLINICAL MICRO-BIOLOGY

## INTRODUCTION OF THE ALL NEW STATE OF ART PET-CT SUITE & SPECT GAMMA CAMERA

PET-CT SUITE / SPECT GAMMA CAMERA / MRI 3T / CARDIAC CT / 4D ULTRASOUND / COLOR DOPPLER / ECHO / TMT / DIGITAL X-RAY / MAMMOGRAPHY / BMD / EEG / EMG / NCV / VEP / ECG / LABORATORY MEDICINE

Permanent ID : P1079090

Registration No.: 101945014

Patient Name: Baby CHITRAKSHI

Age/Sex: 6 Yrs Female

ID Card No.:

Referred By: Dr. Paed Surgery

Referring Hosp.: AIIMS Hospital New Delhi



Mobile No. 9457610125

Registration Dt./Tm.: 13/08/2019 14:08:12

Sample Col. Dt./Tm.: 13/08/2019 14:19:51

Sample Acc. Dt./Tm.: 13/08/2019 16:34:51

Report Dt./Tm.: 13/08/2019 18:44:24

### Investigations

**Result Biological Ref. Interval Units**

#### Haematology

#### Complete Haemogram (CBC with ESR), Whole Blood EDTA

Haemoglobin (Hb) Whole Blood EDTA, Cyanmethaemoglobin Method	11.0	11.0 - 14.0	g/dL
RBC Count Whole Blood EDTA, Electrical Impedance	3.69	4.00 - 5.20	millions/cu.mm
PCV (Haematocrit) Whole Blood EDTA, Pulse Height Detection Method	32.6	34.0 - 40.0	%
MCV Whole Blood EDTA, Calculated	88.0	75.0 - 87.0	fL
MCH Whole Blood EDTA, Calculated	30.0	24.0 - 30.0	Picogram
MCHC Whole Blood EDTA, Calculated	33.9	31.0 - 37.0	gm/dL
TLC (Total Leukocyte Count) Whole Blood EDTA, Electrical Impedance	7.3	5.0 - 15.0	X10 <sup>3</sup> /uL

#### Differential Leukocyte Count (DLC)

Neutrophils Whole Blood EDTA, Microscopic	63	40 - 60	%
Lymphocytes Whole Blood EDTA, Microscopic	26	30 - 50	%
Eosinophils Whole Blood EDTA, Microscopic	01	01 - 06	%
Monocytes Whole Blood EDTA, Microscopic	10	02 - 08	%
Basophils Whole Blood EDTA, Microscopic	00	00 - 01	%
RDW-CV Whole Blood EDTA, Calculated	13.4	11.5 - 14.5	%
Platelet Count Whole Blood EDTA, Electric Impedance/Microscopy	202	200 - 490	X10 <sup>3</sup> /uL
ESR (Erythrocyte Sedimentation Rate) Whole Blood EDTA, OPTOELECTRONIC	32	00 - 20	mm/1st hr

*Self affected*  
*27/11/19*

### "FOCUS... HEALTHCARE BEYOND IMAGINATION"™

Corporate Office & Diagnostic Facilities:  
Laboratory Medicine Hub:  
Focus Helpline Numbers :

C-10, Green Park Extension, New Delhi-16 (MRI @ 3 Tesla, General Radiology Division)  
H-10, Green Park Extension, New Delhi-16 (PET-CT, MRI @ 3 Tesla, General Radiology Division, Cardiac CT Scan)  
7/1-4, Yusuf Sarai Market, Aurobindo Marg, New Delhi-16 (SPECT Gamma Camera & Laboratory Medicine Division)  
+91 11 42199991 | +91 11 42199992 | +91 11 42199993 | +91 11 49490909

Website: www.focusimaging.co.in | E-mail: info@focusimaging.co.in

Focus Helpline Numbers For Laboratory Medicine Reports / Sample Collection queries : +91 11 42199999 • +91 9310683525 • +91 9310055365

ACCREDITED BY A.E.R.B. FOR RADIOLOGY SAFE PRACTICES

● Clinical Correlation is essential for final diagnosis ● If test results are unsatisfactory, please contact personally ● This report is for personal use of doctors only ● Not for medico-legal cases ● All congenital anomalies in a foetus may not be diagnosed in routine obstetric ultrasound

ON PANEL : CGHS, ESI, MCD, ECHS, DGEHS

AN ISO 9001 : 2015 CERTIFIED HEALTHCARE FACILITY  
ACCREDITED BY NABH FOR MEDICAL IMAGING SERVICES AS PER SCOPE

Tests Marked With \* Are Not Covered in NABL Scope.

DOWNLOAD OUR MOBILE APP FROM GOOGLE PLAY STORE



Focus Helpline Numbers For PET-CT & SPECT Gamma Camera Appointments / Queries : +91 11 49490901 • +91 11 49490902 • +91 11 49490903  
• +91 9873494949 • +91 9999816726 • +91 9310159916 • +91 9310683507/39/20 • +91 9810157570

Permanent ID : P1079090



**Registration No.: 101945014**

Mobile No. 9457610125

Patient Name: Baby CHITRAKSHI

Registration Dt./Tm.: 13/08/2019 14:08:12

Age/Sex: 6 Yrs Female

Sample Col. Dt./Tm.: 13/08/2019 14:19:51

ID Card No.:

Sample Acc. Dt./Tm.: 13/08/2019 16:34:51

Referred By: Dr. Paed Surgery

Report Dt./Tm.: 13/08/2019 18:44:24

Referring Hosp.: AIIMS Hospital New Delhi

**Investigations**

**Result**

**Biological Ref. Interval**

**Units**

**Dr. Sudhir Vatsa**  
MBBS, MD (Pathology)  
Senior Consultant Pathologist  
DMC Reg No.: 32570  
**Dr. Asif Baliyan**

Self attested

27/11/19





# FOCUS IMAGING & RESEARCH CENTRE PVT. LTD.

• NUCLEAR MEDICINE • DIAGNOSTIC RADIOLOGY • NON-INVASIVE CARDIOLOGY • NEURO-ELECTROPHYSIOLOGY • LABORATORY MEDICINE • PREVENTIVE HEALTHCARE



NABH & NABL ACCREDITED FACILITY AS PER SCOPE



• CLINICAL HEMATOLOGY • CLINICAL PATHOLOGY • CLINICAL BIO-CHEMISTRY • CLINICAL MICRO-BIOLOGY

## INTRODUCTION OF THE ALL NEW STATE OF ART PET-CT SUITE & SPECT GAMMA CAMERA

PET-CT SUITE / SPECT GAMMA CAMERA / MRI 3T / CARDIAC CT / 4D ULTRASOUND / COLOR DOPPLER / ECHO / TMT / DIGITAL X-RAY / MAMMOGRAPHY / BMD / EEG / EMG / NCV / VEP / ECG / LABORATORY MEDICINE

Permanent ID : P1079090

Registration No.: 101945014

Patient Name: Baby CHITRAKSHI

Age/Sex: 6 Yrs Female

ID Card No.:

Referred By: Dr. Paed Surgery

Referring Hosp.: AIIMS Hospital New Delhi

Mobile No. 9457610125

Registration Dt./Tm.: 13/08/2019 14:08:12

Sample Col. Dt./Tm.: 13/08/2019 15:18:53

Sample Acc. Dt./Tm.: 13/08/2019 16:34:51

Report Dt./Tm.: 13/08/2019 18:26:42

### Investigations

Result Biological Ref. Interval Units

### Biochemistry

#### Liver Function Test (LFT)

Total Protein, Serum Serum, Biuret	6.0	6.6 - 8.3	g/dl
Albumin Serum Serum, Bromocresol green	4.14	3.50 - 5.20	gm/dL
Globulin, Serum Serum, Calculated	1.9	2.3 - 3.5	gm/dL
A:G (Albumin:Globulin) Ratio Serum, Calculated	2.18	1.50 - 2.50	
SGOT/AST (Aspartate Amino-transferase) Serum, IFCC, Without P-S-P	36.0	0.0 - 35.0	IU/L
SGPT/ALT (Alanine Amino-transferase) Serum, IFCC, Without P-S-P	13.0	0.0 - 35.0	IU/L
ALP (Alkaline Phosphatase) Serum, Kinetic, IFCC	176.0	54.0 - 369.0	U/L
GGTP (Gamma Glutamyl-transpeptidase) Serum Serum, IFCC	11	7 - 32	IU/L
Bilirubin, Total, Serum Serum, DPD	0.3	0.3 - 1.2	mg/dL
Bilirubin, Direct, Serum Serum, DPD	0.08	0.00 - 0.20	mg/dL
Bilirubin, Indirect, Serum Serum, Calculated	0.22	0.10 - 0.50	mg/dL

*Self attested*  
*[Signature]*  
27/11/19

*[Signature]*

**Dr. Asif Baliyan**  
MBBS, MD (Pathology)  
Consultant Pathologist  
DMC Reg No.: 60527

### "FOCUS... HEALTHCARE BEYOND IMAGINATION"®

Corporate Office & Diagnostic Facilities: C-10, Green Park Extension, New Delhi-16 (MRI @ 3 Tesla, General Radiology Division)  
 Laboratory Medicine Hub: H-10, Green Park Extension, New Delhi-16 (PET-CT, MRI @ 3 Tesla, General Radiology Division, Cardiac CT Scan)  
 Focus Helpline Numbers: 7/1-4, Yusuf Sarai Market, Aurobindo Marg, New Delhi-16 (SPECT Gamma Camera & Laboratory Medicine Division)  
 +91 11 42199991 | +91 11 42199992 | +91 11 42199993 | +91 11 49490909

Website: www.focusimaging.co.in | E-mail: info@focusimaging.co.in  
Focus Helpline Numbers For Laboratory Medicine Reports / Sample Collection queries: +91 11 42199999 +91 9310683525 +91 9310055365

ACCREDITED BY A.E.R.B. FOR RADIOLOGY SAFE PRACTICES

The Logo & A/Work including the Tag Line "FOCUS... HEALTHCARE BEYOND IMAGINATION" are Registered Trademarks of FOCUS IMAGING AND RESEARCH CENTRE PVT. LTD. Any Unauthorised Copying/ Duplication is liable for Legal Action  
 • Clinical Correlation is essential for final diagnosis • If test results are unsatisfactory, please contact personally • This report is for personal use only • Not for medico legal cases • All congenital anomalies in a foetus may not be diagnosed in routine obstetric ultrasound.

ON PANEL: CGHS, ESI, MCD, ECHS, DGHs

AN ISO 9001 : 2015 CERTIFIED HEALTHCARE FACILITY  
ACCREDITED BY NABH FOR MEDICAL IMAGING SERVICES AS PER SCOPE  
Tests Marked With \* Are Not Covered in NABL Scope.

DOWNLOAD OUR MOBILE APP FROM GOOGLE PLAY STORE



Focus Helpline Numbers For PET-CT & SPECT Gamma Camera Appointments / Queries: +91 11 49490901 +91 11 49490902 +91 11 49490903

+91 9873494949 +91 9999816726 +91 9310159916 +91 9310683507/39/20 +91 9810157570

Permanent ID : P1079090

**Registration No.: 101945014**

Patient Name: Baby CHITRAKSHI

Age/Sex: 6 Yrs Female

ID Card No.:

Referred By: Dr. Paed Surgery

Referring Hosp.: AIIMS Hospital New Delhi

Mobile No. 9457610125

Registration Dt./Tm.: 13/08/2019 14:08:12

Sample Col. Dt./Tm.: 13/08/2019 15:18:53

Sample Acc. Dt./Tm.: 13/08/2019 16:34:51

Report Dt./Tm.: 13/08/2019 18:26:42



**Investigations**

**Result Biological Ref. Interval Units**

**Kidney Function Test (KFT)**

Urea, Serum <small>Serum, Urease Glutamate Dehydrogenase</small>	17	17 - 43	mg/dL
Creatinine, Serum <small>Serum, Jaffes</small>	<b>0.50</b>	0.55 - 1.20	mg/dL
Uric Acid, Serum <small>Serum, Uricase</small>	4.33	2.60 - 6.00	mg/dL
Sodium, Serum <small>Serum, Ion Selective Electrode</small>	141	136 - 145	mEq/L
Potassium, Serum <small>Serum, Ion Selective Electrode</small>	4.3	3.5 - 5.5	mEq/L
Chloride Serum <small>Serum, Ion Selective Electrode</small>	99	95 - 107	mEq/L
Phosphorus, Serum <small>Serum, Direct Phosphomolybdate</small>	3.3	2.5 - 4.5	mg/dL
Calcium, Serum <small>Serum, Arsenazo III</small>	9.2	8.8 - 10.6	mg/dL

**Dr. Asif Baliyan**  
MBBS, MD (Pathology)  
Consultant Pathologist  
DMC Reg No.: 60527



# सोमती नर्सिंग होम

डा० सोमती केन

MBBS, DGO (KGMC) IFUMB

प्रसूति एवं स्त्री रोग विशेषज्ञ एवं सर्जन

डा० नरेन्द्र केन

MBBS, D.M.R.D., I.F.U.M.B., M.I.R.I.A.

अल्ट्रासोनोलोजिस्ट एवं रेडियोलोजिस्ट

Dated.....

Pt's Name	Chitrakshi	Age/ Sex	5Y / F
Under Care of	SELF		10 August 2019

## USG WHOLE ABDOMEN

LIVER - mildly enlarged in size. Shape is maintained. Echogenecity of liver maintained. No echovariant lesion seen in liver parenchyma. no IHBRD seen. Caudate lobe normal. Diameter of hepatic vein maintained.

GALL BLADDER distended in size. no stone seen in lumen of GB.

CBD AND PV - normal in course and caliber.

PANCREAS - normal in size and shape. Pancreatic duct not dilated.

SPLEEN - normal in size and shape. Echogenecity of spleen maintained.

No echo variant lesion seen in splenic parenchyma.

BOTH KIDNEYS - normal in size and shape. no hydronephrosis present in both kidneys CM differentiation maintained on both side. Perirenal spaces is clear. Parenchymal thickness maintained on both side. Surface of both kidneys regular.

BOTH URETERS - not dilated,

URINARY BLADDER - distended

UTERUS normal in size and shape

No free fluid seen in b/l pleural and peritoneal cavity.

## OPINION.

Mild hepatomegaly present. bowel wall thick irregular and edematous.

Multiple 12-14 mm mesnetric lymph nodes present

ADV BLOOD EXAMINTION WITH LFT/ALP/ ESR

PLEASE CORELATE CLINICALLY.

Self attested  
27/11/19

DR NARENDER KAIN  
MBBS DMRD MIRIA IFUMB  
RADIOLOGIST

(प्रत्येक रविवार साँय की OPD बन्द रहेगी)

CT-SCAN की सुविधा 24 घन्टे उपलब्ध है।

कवि नगर, गढ़ चुंगी, गढ़ रोड, हापुड़, Ph : No. 0122-2334455, 9837085256

समय : सुबह 10.00 बजे से 2.00 बजे तक  
सायं 6.00 बजे से 8.00 बजे तक

मेडिकोलीगल उपयोग  
के लिए नहीं

रंगीन अल्ट्रासाऊण्ड की विशेष  
सुविधा उपलब्ध है।

जापान की अत्याधुनिक व हापुड़ की सबसे बड़ी एक्सरे मशीन के द्वारा एक्सरे की सुविधा



भारतीय विशिष्ट पहचान प्राधिकरण  
भारत सरकार  
Unique Identification Authority of India  
Government of India

नामांकन क्रम/ Enrolment No.: 2189/53998/00023

To  
विवाशी सिंह  
Chitrakshi Singh  
D/O: Ompal Singh  
ward no 14  
naya bans  
Bakhtawarpur  
Gam Bridge Halt  
Hapur Uttar Pradesh - 245205  
9634340549

Download Date: 17/05/2018  
Generation Date: 05/08/2017

Signature Not Verified  
Details shared by the  
UNIQUE IDENTIFICATION  
AUTHORITY OF INDIA  
Date: 2018-05-17 12:21:44  
BT



QR Code with photograph

आपका आधार क्रमांक / Your Aadhaar No. :

9707 9832 3448

VID : 9154 3048 5402 7952

मेरा आधार, मेरी पहचान



भारत सरकार  
Government of India



विवाशी सिंह  
Chitrakshi Singh  
जन्म तिथि/DOB: 15/11/2013  
महिला/ FEMALE

9707 9832 3448

VID : 9154 3048 5402 7952


मेरा आधार, मेरी पहचान



भारतीय विशिष्ट पहचान प्राधिकरण  
Unique Identification Authority of India

पता:  
आम्बला: ओम्पाल सिंह, बॉर्ड न 14, नया बंस, बख्तावरपुर,  
हापुर,  
उत्तर प्रदेश - 245205


Address:  
D/O: Ompal Singh, ward no 14, naya bans,  
Bakhtawarpur, Hapur,  
Uttar Pradesh - 245205



QR Code with photograph

9707 9832 3448

VID : 9154 3048 5402 7952



- सूचना
- आधार पहचान का प्रमाण है, नागरिकता का नहीं।
  - पहचान का प्रमाण ऑनलाइन ऑथेंटिकेशन द्वारा प्राप्त करें।
  - यह एक इलेक्ट्रॉनिक प्रक्रिया द्वारा बना हुआ पत्र है।

नोट: बच्चे १५ वर्ष की उम्र होने पर बायोमेट्रिक विशिष्टताओं का नवीनीकरण कराएँ।

INFORMATION

- Aadhaar is a proof of identity, not of citizenship.
- To establish identity, authenticate online.
- This is electronically generated letter.

Note: Children on attaining 15 years of age need to update biometric information.

- आधार देश भर में मान्य है।
- आधार भविष्य में सरकारी और गैर-सरकारी सेवाओं का लाभ उठाने में उपयोगी होगा।
- Aadhaar is valid throughout the country.
- Aadhaar will be helpful in availing Government and Non-Government services in future.

Self attested





भारत सरकार  
Government of India



कोटेश कुमार  
Kotesch Kumar  
जन्म तिथि/DOB: 24/09/2016  
पुल्ल/ MALE

यस आधार 5 वर्ष की उम्र तक ही वैध है।

**7376 2370 0170**

VID: 9132 8175 4128 4631



मेरा आधार, मेरी पहचान




भारतीय विश्वविद्यालय पहचान प्राधिकरण  
Unique Identification Authority of India

आधार

पता:  
आलय: ओम पाल सिंह, 108, नया बंस, बखतारपुर,  
हापुर,  
उत्तर प्रदेश - 245205

Address:  
S/O. Om Pal Singh, 108, naya bans,  
Bakhtawarpur, Hapur,  
Uttar Pradesh - 245205



QR Code with Photograph

**7376 2370 0170**

VID: 9132 8175 4128 4631

Self attested  
*[Signature]*

