



MUSKAN HOSPITAL
15/08/20 12:22:03PM

ASTHA
ADM 150820-121609PM

10w4d LMP

Origin LMP LMP 02/06/2020 BBT GA 10w4d EDD(LMP) 09/03/2021
 Fetus A/1 CUA 10w6d+/-0w5d EDD(CUA) 07/03/2021
 FetusPos 1 PLAC Page 1/1

B Mode Measurements

GS(Hollman) 5.05 cm 5.05 Avg. 10w6d 9w6d-11w6d
 CRL(Hadlock) 3.88 cm 3.88 Avg. 10w5d 10w2d-11w2d

Doppler Measurements

OB-1

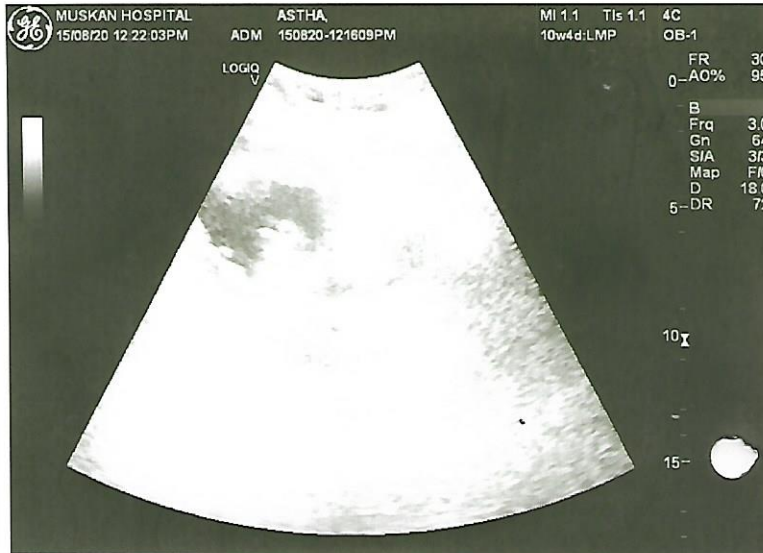
Time 0.809 s 0.809 Max
 HR 148.32 bpm 148.32



MUSKAN HOSPITAL
15/08/20 12:22:03PM

ASTHA
ADM 150820-121609PM

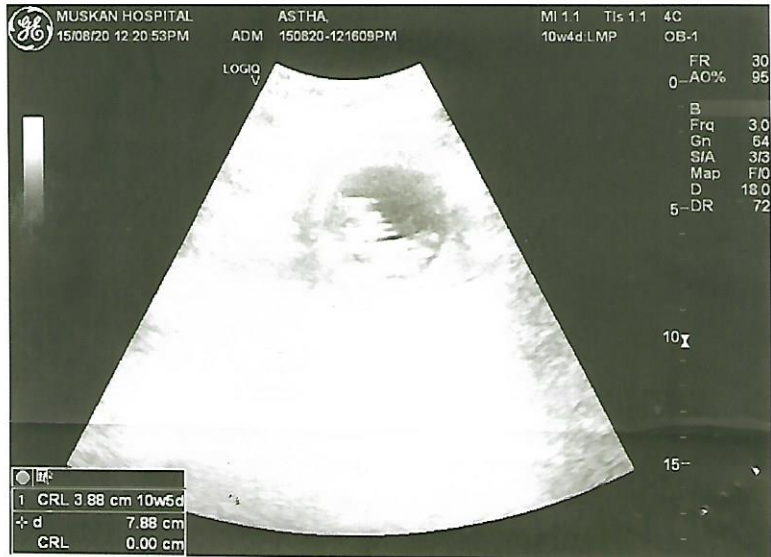MI 1.1 TIs 1.1 4C
10w4d LMP OB-1

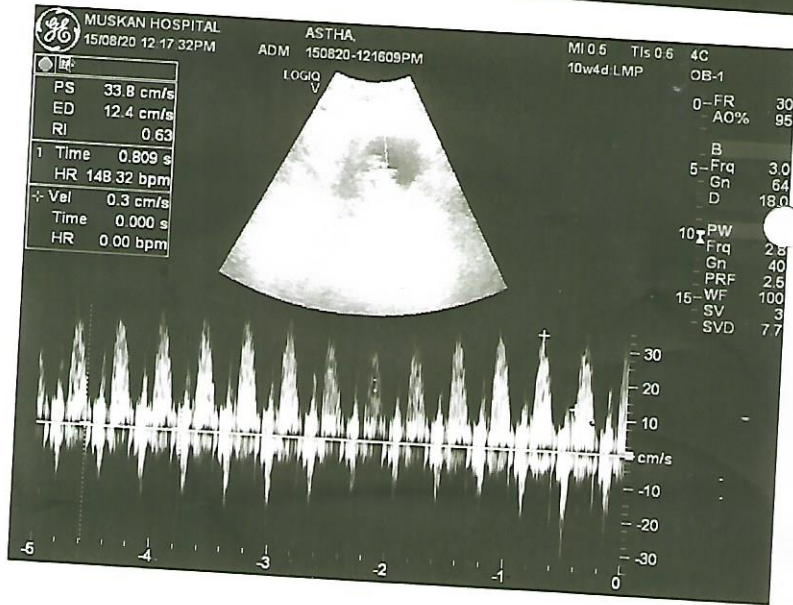
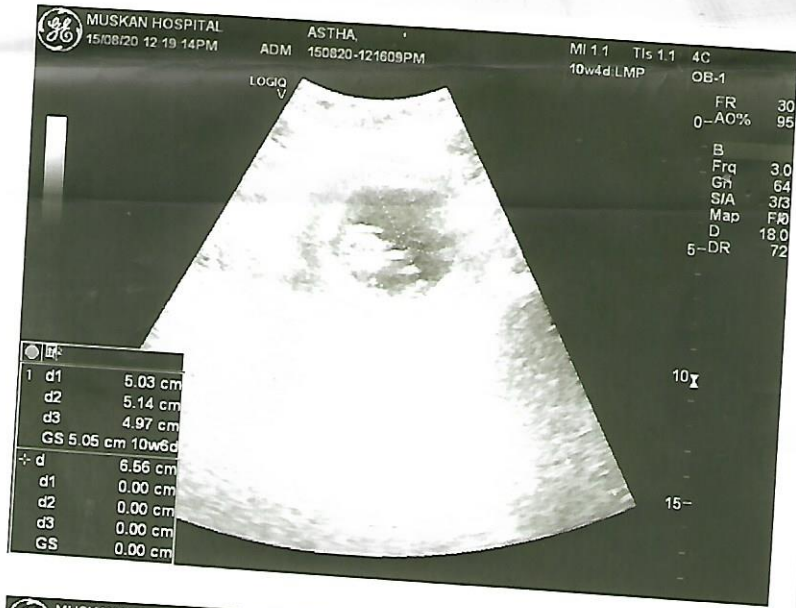


MUSKAN HOSPITAL
15/08/20 12:20:53PM

ASTHA
ADM 150820-121609PM

MI 1.1 TIs 1.1 4C
10w4d LMP OB-1





MUSKAN-HOSPITAL, UNNAO

B-1071, Awas Vikas Colony Unnao-209801 Ph.-0515-2830882

ULTRASONOGRAPHY REPORT

Patient's Name: - Ms Astha Age/Sex:- Date: - 15/8/20
Referred By Dr.:- Rekha Singh
Ultrasound for FWB

L.M.P.: 2/6/2020

E.D.D. (according to L.M.P.): 9/3/2021

E.D.D. (according to USG): 7/3/2021

- A single live Intra Uterine embryo seen with in the gestational sac measuring 5.05 cm and gestational age 10 weeks 6 days.
- CRL measuring 3.88 cm and gestational age 10 weeks 5 days.
- Yolk sac seen.

FEATAL CARDIAC STATUS:-

- ❖ Cardiac activity present. Fetal heart rate is 148 bpm

IMPRESSION

Single live Intrauterine fetus gest. age 10 weeks 6 days
Cardiac Activity seen.

Declaration:- I have neither detected nor disclosed sex of fetus to any body.


Dr Rekha Singh